

# Accepted Manuscript

Tumour Review

Management of metastatic bladder cancer

Rosa Nadal, Joaquim Bellmunt

PII: S0305-7372(19)30054-4

DOI: <https://doi.org/10.1016/j.ctrv.2019.04.002>

Reference: YCTRV 1867

To appear in: *Cancer Treatment Reviews Cancer Treatment Reviews*

Received Date: 7 December 2018

Revised Date: 9 April 2019

Accepted Date: 11 April 2019

Please cite this article as: Nadal, R., Bellmunt, J., Management of metastatic bladder cancer, *Cancer Treatment Reviews Cancer Treatment Reviews* (2019), doi: <https://doi.org/10.1016/j.ctrv.2019.04.002>

This is a PDF file of an unedited manuscript that has been accepted for publication. As a service to our customers we are providing this early version of the manuscript. The manuscript will undergo copyediting, typesetting, and review of the resulting proof before it is published in its final form. Please note that during the production process errors may be discovered which could affect the content, and all legal disclaimers that apply to the journal pertain.



**Date:** November 2018

**For:** *Cancer Treatment Reviews*

## **Management of metastatic bladder cancer**

Rosa Nadal<sup>a</sup> and Joaquim Bellmunt<sup>b</sup>

<sup>a</sup>Author affiliation

*Cellular and Molecular Therapeutics Branch, National Heart, Lung, and Blood Institute,  
National Institutes of Health, Bethesda, MD USA*

<sup>b</sup>Author affiliation

*Associate Professor of Medicine, Harvard Medical School, Boston, MA USA  
IMIM-Hospital del Mar Medical Research Institute*

\*Corresponding author at:

*Joaquim Bellmunt Molins, MD, PhD*

*IMIM-Hospital del Mar Medical Research Institute*

*PRBB Building (office 100.06.02)*

*Doctor Aiguader, 88, 1rst floor*

*08003 Barcelona*

*Tel. +34933 161 780 | Fax +34 933 160 410*

*[jbellmunt@imim.es](mailto:jbellmunt@imim.es)*

**Keywords:** Metastatic urothelial carcinoma, systemic therapy, molecular characterization, immune checkpoint inhibitors, *FGFR* genetic alterations

**Abstract**

Important advances in the understanding of the biology and mechanisms of tumor progression of urothelial carcinoma (UC) have been achieved over the past decade. The treatment landscape for advanced-stage, unresectable or metastatic UC has shifted dramatically over a short period of time, with 5 new therapeutic agents available for clinical use. The use of traditional chemotherapy and new immune checkpoints inhibitors (ICIs) directed at programmed cell-death protein 1 (PD-1) or its ligand has led to unprecedented survival benefits in selected patients with metastatic UC. Data show that anti-PD-1 ICIs are not only improving long-term clinical benefit, but also quality of life for patients in the second-line setting. In the front-line setting, regulatory agencies have restricted the indications of atezolizumab and pembrolizumab (both ICIs) to patients with PD-L1 positivity with advanced UC and who are platinum-ineligible. Meanwhile, erdafitinib, a pan-FGFR inhibitor, and enfortumab vedotin, an antibody-drug conjugate, have been granted breakthrough designation by the FDA for the treatment of metastatic UC. Here we review the clinical trial data that have established standard-of-care treatment for advanced-stage UC. In addition, mechanisms of resistance and biomarkers of response to platinum-based chemotherapies and immunotherapies are also discussed, along with the clinical benefits and limitations of these therapies.

## Introduction

Bladder cancer is among the most prevalent cancers worldwide, with around 430,000 new diagnoses each year [1]. Most UC develops in the urinary bladder and is derived from the pseudostratified epithelium known as the urothelium. Considerably fewer UCs develop in the renal pelvis and ureter (upper tract), which are also lined by urothelium. Tumors that invade the detrusor muscle are considered muscle-invasive bladder cancer (MIBC) and are more likely to metastasize to lymph nodes or other organs. Approximately 75% of newly diagnosed patients have non-muscle-invasive bladder cancer with the remaining 25% having MIBC [2] or metastatic disease [3]. While early diagnosis and multimodality therapy results in optimal patient outcomes, metastatic disease is generally incurable, with a relative 5-year overall survival (OS) rate of 15%.

While platinum-based chemotherapy remains a standard treatment for advanced UC, treatment options have changed dramatically since the U.S. Food and Drug Administration's (FDA) approval of 5 immune-checkpoint agents. After decades of disappointing results in trials in metastatic UC, immunotherapeutic antibodies directed at PD-1 and its ligand (PD-L1) are finally in routine clinical settings (Table 1). Outstandingly, pembrolizumab showed in a phase III trial to be associated with improved OS and quality of life, compared with chemotherapy. This finding has shifted second-line therapy from single-agent chemotherapy to ICIs, leading to durable responses in a relevant proportion of patients. Importantly, ICIs have a manageable safety profile, making them an attractive option for both cisplatin-eligible and cisplatin-ineligible populations, including elderly patients and those with poor performance status. Although no prospective analysis of the optimal choice of front-line treatment has been completed, ICIs have

also been introduced in the first-line setting for PD-L1-positive and platinum-ineligible patients with metastatic UC. Moreover, two new agents have gained breakthrough therapy designation by the FDA. First, erdafitinib, an oral pan-fibroblast growth factor receptor (FGFR)-targeted agent, which has shown relevant clinical activity in metastatic UC patients whose tumors bear actionable *FGFR* alterations. Second, enfortumab vendotin, an antibody-drug conjugate targeting nectin-4, for patients with locally advanced or metastatic UC who previously received ICIs.

Characterization of tumors at the whole-genome level from large cohorts of patients with advanced-stage UC has provided greater granularity regarding the prevalence of genetic alterations and their impact on treatment response. For example, the discovery of a subset of UC harboring FGFR genetic alterations led to the development of FGFR inhibitors or the observation that  $PPAR\gamma^{\text{high}}/RXR\alpha^{S427F/Y}$  impairs CD8<sup>+</sup> T-cell infiltration as underlying mechanism of resistance to ICIs in MIBC. [4,5] Following is a summary of the state of the field and a review of the clinical trial data that established standard-of-care treatment approaches for advanced UC.

### **Molecular landscape of urothelial carcinoma**

A broad range of clinical outcomes has suggested the existence of biologically relevant subtypes of UC. Initial MIBC analyses identified 2 major tumor groups—luminal and basal. Further analyses have defined 3 [6], 4 [7,8], and subsequently 5 [7,8] molecular subtypes. These projects have provided information not only on the genetic drivers but also on the subtypes or clusters of MIBC. Transcriptional profiles currently provide the best-defined subtypes.

The Cancer Genome Atlas (TCGA) project for bladder cancer involved 2 major studies, the first with 131 patients [7] and a subsequent study expanded to 412 patients [8].

The initial integrated genomic analysis of 131 bladder cancer samples demonstrated a high somatic mutation rate (median 5.5/megabase), with significant recurrent mutations in 32 genes. The TCGA's expanded cohort analysis in 2017 identified a significantly greater number of mutated genes (from 32 in 2014 to 64 in 2017) and hundreds of gene fusions, confirming the high mutation rate of MIBC. These alterations were organized into distinct mutational signatures and canonical signaling pathways, including those involved in p53/cell cycle, DNA repair, PI3K/AKT, RTK/MAPK, and chromatin modifications and regulation. The 412 bladder cancer cases analyzed could also be separated into 4 major groups based on distinct mutational signatures, including one associated with mutation of excision repair cross complementing 2 (*ERCC2*) [9] and 2 others associated with patterns of mutagenesis by APOBEC cytidine deaminases [10]. APOBEC-related mutational signature, high mutational burden, and high neoantigen load were each associated with improved survival [8]. Furthermore, RNA expression analysis identified 5 expression subtypes: luminal-papillary (35%), luminal (6%), basal-squamous (35%), luminal-infiltrated (19%), and neuronal (5%) [8]. The 5 major TCGA subtypes were reflected in an independent dataset of 303 bladder cancers [11]. The association between molecular subtypes and treatment response is discussed in subsequent sections.

### **The importance of baseline characteristics**

The use of cisplatin-based chemotherapy has been limited by toxicities experienced by UC patients, whose frequent comorbidities limit their ability to tolerate aggressive therapy. It is estimated that only half of the patients with advanced disease are candidates for or receive a cisplatin-based chemotherapy regimen [12]. Patients included in clinical trials are deemed cisplatin-ineligible based on the following criteria: Eastern Cooperative Oncology Group

performance status of  $\geq 2$  or a Karnofsky performance status of  $\leq 60\%$ – $70\%$ ; creatinine clearance  $< 60$  mL/min; hearing loss (measured at audiometry) of 25 dB at 2 contiguous frequencies; grade  $\geq 2$  peripheral neuropathy; or New York Heart Association class  $\geq 3$  heart failure [13]. Impaired kidney function is a frequent feature of UC, either from direct obstruction or infiltration of urothelial tumors or due to other comorbidities commonly associated with this disease. An expert consensus statement suggested a glomerular filtration rate (eGFR) of  $> 60$  mL/min as optimal for the use of cisplatin-based chemotherapy [13].

Some clinicians have made use of a split-dose regimen for borderline cases with calculated creatinine clearance of 40–60 mL/min, where cisplatin is separated across 2 treatment days. There have been no obvious differences in tolerability or outcomes between standard and spit-dose regimens, although no randomized comparisons have been performed [14,15]. In most oncology practices, such patients typically receive aggressive hydration (3 L pre/post-cisplatin) to improve renal perfusion with mandatory urological procedures (including nephrostomy tubes) to decompressed obstructed kidneys. Thus, patient characteristics are still critical for patient management and are the foundation for most of the proposed treatment management algorithms (Fig. 1).

### **Selecting treatment based on molecular testing**

Despite recent discoveries of molecular alterations in UC, their prognostic and clinical implications are unclear. However, in the context of current clinical practice, *FGFR* alterations, PD-L1 status and certain DNA Damage Response (DDR) and repair gene alterations may guide treatment management in selected settings.

Activating point mutations of *FGFR3* are very common in low-grade and early-stage bladder tumors. TCGA network identified a relevant 12% of MIBC having *FGFR3* mutations and 3% translocations involving *FGFR3* with oncogenic *FGFR3* fusions being seen more commonly in high-grade, invasive tumors [16]. Although still unclear, recent work has pointed out that luminal cluster (enriched for *FGFR* genomic alteration) is associated with lower expression levels of CD8<sup>+</sup> genes and reduced response to ICIs [17]. Another study has found that higher *FGFR3* expression and *FGFR3* pathway mutations strongly correlate with immune exclusion in UC [18]. These observations suggest that patients harboring *FGFR3* alterations are relatively poor candidates for ICI therapy, and that possible approaches for such cold UC could include the use of FGFR inhibitors. [7,8]

The finding of aberrant FGFR signaling in metastatic UC and the limited therapeutic options for those tumors harboring *FGFR gene* alterations has led to major interest in exploitation for therapy during the past decade. Erdafitinib, a pan-FGFR inhibitor, induced a 42% overall response rate in patients who had metastatic or surgically unresectable UC with a verified mutation in *FGFR3* or fusion in *FGFR2* or *FGFR3*. Interestingly, more than two thirds of patients who previously had been treated with ICIs had an objective response to erdafitinib [19]. This is an important milestone as we work to bring new treatment options for molecularly selected metastatic UC patients.

Bearing in mind all the caveats of using different non-standardized PD-L1 assays, some correlative data suggest that patients with high PD-L1 expression have a favorable response to PD-1/PD-L1 blockade. However, PD-1/PD-L1 blockade has also shown benefit in patients with low PD-L1 expression. Based on this finding, PD-1/PD-L1 blockade agents are



being prescribed to treat metastatic UC irrespective of PD-L1 expression status in the second-line setting [17,20-23]. In contrast, there is divergent evidence on the correlation of PD-L1 status and clinical outcome with pembrolizumab (as measured by combined positive score [CPS], which measures the percentage of PD-L1<sup>+</sup> tumor cells and infiltrating immune cells relative to the total number of tumor cells) and atezolizumab (as measured by PD-L1 expression on tumor-infiltrating cells) in the first-line setting. To generate more controversy and with lack of revelation of data, regulatory approval of these two agents in first line requires high expression of PD-L1 [24,25].

Better predictors for response to immunotherapy are critical for ICIs optimal use. Although not clinically validated, one of the strongest predictive features of tumors that are likely to respond was found to be a high density of tumor-infiltrating CD8<sup>+</sup> lymphocytes, which can be assessed by immunohistochemistry (IHC) [26]. Response to ICIs has also been shown to correlate with tumor mutational load (TML) and mismatch repair (MMR) pathway status. The impact of TML on response to ICI was explored in the IMvigor210 and CheckMate 215 clinical trials, as described below [17,27]. UCs with DNA MMR deficiency, which can be seen in genetic syndromes such as Lynch syndrome (hereditary non-polyposis colorectal cancer) and tumors involving the upper tract, appear to be particularly responsive to ICIs [28,29].

Beyond ICIs, alterations in DNA repair pathways are attractive biomarkers for cisplatin sensitivity, as the majority of such alterations reduce cells' ability to repair DNA damage. Initial retrospective studies testing this hypothesis found that tumors with low excision repair cross complementing 1 (*ERCC1*) mRNA expression were associated with longer survival [30]. This association was confirmed in a subsequent meta-analysis of 1475 patient with advanced UC

treated with platinum-based chemotherapy [31]. More recently, other investigators have demonstrated that somatic mutations in genes that encode DDR proteins are associated with significantly improved clinical outcomes in metastatic UC [32]. In this study [32], roughly half of patients had  $\geq 1$  DDR alterations in  $\geq 1$  of the 34 DDR-associated genes analyzed. Patients with  $\geq 1$  DDR alterations had significantly longer progression-free survival (PFS; 9.3 vs 6.0 months;  $P = 0.007$ ) and OS (23.7 vs 13.0 months;  $P = 0.006$ ) with platinum-based therapy compared to those with no detectable DDR alterations. This finding is being externally confirmed and validated in a randomized phase III study of gemcitabine or cisplatin with or without bevacizumab (NCT00942331).

### **First-line chemotherapy for metastatic disease**

Cisplatin-based combination chemotherapy such as methotrexate, vinblastine, doxorubicin, and cisplatin (MVAC) or gemcitabine-cisplatin (GC) is the standard of care for patients with metastatic UC, as supported by level 1 evidence.

Historically, MVAC had been considered the standard therapy for treating advanced bladder cancer. The efficacy of MVAC was first reported in the 1980s in a single-arm study [33] and subsequently compared to single-agent cisplatin in a multicenter phase III trial. MVAC was shown to provide a survival advantage over cisplatin alone (median survival: 12.5 vs 8.2 months, respectively) [34]. In another randomized study, MVAC resulted in higher response rates and longer survival than a combination of cisplatin, cyclophosphamide, and doxorubicin (median survival: 48 vs 40 weeks, respectively) [35].

Despite superior outcomes with MVAC, its use has been severely limited by substantial toxicities, including neutropenia, mucositis, cardiac and neurologic toxicities, and a significant

3%–4% death rate [33,34]. In an attempt to improve tolerability, the combination of GC was studied in a random comparison with MVAC in the same population. In 3 phase II trials, GC had comparable activity with MVAC with a better toxicity profile [36-38]. Soon after, a randomized trial designed to demonstrate superior efficacy of GC over MVAC showed comparable antitumor efficacy [39] with similar overall response rate (ORR) (GC 49%; MVAC 46%). Long-term follow-up also confirmed no difference in survival (GC 13%; MVAC 15.3%) [40]. The better toxicity profile and lower death rate with GC led to fairly wide adoption of GC as standard first-line therapy for metastatic bladder cancer.

The addition of new agents or the practice of dose intensification, have not resulted in substantially improved clinical outcomes. A randomized phase III trial evaluating classic MVAC vs dose-dense (DD) MVAC found that DD MVAC did not improve median survival (HR: 0.76; 95% CI: 0.58–0.99) [41]. The toxicity profile of DD MVAC appeared to be better compared to standard-dose MVAC. Similarly, a phase III randomized study assessing DD GC as a new option comparing DD MVAC vs DD GC as first-line therapy in 174 patients with advanced UC did not result in an improved median OS [42].

Taxanes, studied quite extensively, have shown modest antitumor activity in UC. In the first-line setting, a 3-drug regimen has been compared to a 2-drug regimen. A phase III trial evaluated the addition of paclitaxel to GC (PGC) in locally advanced/metastatic UC with OS as a main endpoint [43]. While response rate with PGC improved from 43.6% to 55.5%, only a trend in OS benefit was observed (14% reduction in risk of death). An unplanned analysis of intended eligible patients with tumors having bladder as primary origin (rather than upper tract) revealed a longer OS (3.2 months; HR: 0.82;  $P = 0.03$ ) [43]. Toxicity is a concern with PGC as increases have been seen in the incidence of some serious (grade 3/4) toxicities, including neutropenia

(65% vs 51%), fatigue (15% vs 11%), and infections (18% vs 14%), but a lower incidence of serious (grade 3/4) thrombocytopenia (35% vs 52%). In the same clinical setting, a randomized phase III trial showed that the combination of larotaxel (a novel semisynthetic taxoid) and cisplatin for locally advanced/metastatic upper-tract or bladder cancer had inferior outcomes compared to the standard combination of GC [44].

Although cisplatin-based regimens are the optimal treatment for metastatic UC, up to half of patients cannot tolerate cisplatin. For these patients, carboplatin plus gemcitabine is the preferred treatment based on the results of the EORTC 30986 trial favoring this regimen [45]. Other combinations have been studied. JASINT-1, an international randomized phase II trial, compared vinflunine plus gemcitabine vs vinflunine plus carboplatin in cisplatin-intolerant patients. This study reported similar disease control rate, ORR, and OS for both vinflunine-based doublets, while hematologic tolerance favored the vinflunine-gemcitabine combination [46].

Traditional first line chemotherapy regimens rarely achieve complete and durable remissions in patients with metastatic UC. Despite low rates of cure, they do offer a longer and better quality of life for such patients.

### **Second-line chemotherapy and beyond for metastatic disease**

Several agents have been investigated in second-line therapy with disappointing outcomes [47-49]. Despite their moderate activity in single-agent phase II trials, taxanes are relatively widely used in the second-line setting or beyond based on consensus recommendations. Paclitaxel has demonstrated response rates of 5%–19% and a median survival of 6.5–7.2 months [50,51]. Docetaxel has similar clinical activity to paclitaxel, but a less favorable toxicity profile [52].

As a single agent, only vinflunine has been assessed in a randomized phase III trial designed to compare OS between patients receiving this agent versus and best supportive care (BSC) vs BSC alone. Although in the intention-to-treat population no benefit in survival was observed, the pre-planned final analysis in the eligible population demonstrated a median OS of 6.9 months for the vinflunine arm vs 4.3 months for the BSC-alone arm, with an estimated 22% reduction in the risk of death ( $P = 0.0227$ ). ORR, disease control, and PFS were also statistically significant in favor of the study drug [53]. Vinflunine is approved by the European Medicines Agency (EMA) and recommended in European guidelines for the treatment of advanced or metastatic UC after failure of platinum-based therapy.

### **Immune checkpoint inhibitors**

Until very recently, no established therapy was available following the failure of platinum-based chemotherapy or for those patients who cannot tolerate platinum chemotherapy. The characterization of immune checkpoints has led to the development of a number of novel immunotherapy agents that have activity in several different diseases, including bladder cancer. Immune checkpoints aim to maintain immune tolerance against self-antigens and to modulate the duration and amplitude of immune responses. For example, the cytotoxic T lymphocyte-associated protein 4 (CTLA-4) receptor and its ligands are mainly expressed in lymph nodes. Inhibition of this pathway leads to a generic enhancement of the immune priming phase, with activation of greater numbers of naïve T cells. This approach was pioneered by monoclonal antibodies against CTLA-4 such as ipilimumab, whose primary period of activity is during the induction phase of antitumor T-cell immunity within lymphoid tissues. Conversely, PD-1 and its ligands PD-L1 and PD-L2 are widely expressed in peripheral tissues, affecting the effector phase of activated T cells. PD-1/PDL-1 inhibitors primarily act within the

tumor microenvironment, with additive and synergistic effects. Several different monoclonal antibodies targeting either PD-1 immune checkpoint or the endogenous ligand, PD-L1, have now been approved by the FDA.

### **Immune checkpoint inhibitors as first-line therapy**

In the first-line setting, the efficacy of atezolizumab in metastatic UC was evaluated in one cohort of the IMvigor210 trial, a 2-cohort phase 2 study. Cohort 1 included 119 cisplatin-ineligible patients with metastatic UC regardless of PD-L1 expression status. This study demonstrated an ORR of 24% and a median OS of 14.8 months [25]. The median PFS was very modest (2.7 months) compared with historical outcomes with chemotherapy (~ 6 months). Most responses were durable and occurred similarly across all PD-L1-defined and poor-prognosis-factor subgroups. Results of a post-hoc analysis showed a substantially higher TML (an exploratory biomarker) in patients with response vs those without a response [25]. In a second trial, the KEYNOTE-052 trial, 370 cisplatin-ineligible patients with advanced UC were treated with pembrolizumab as monotherapy. The primary endpoint was objective response. The response rate to pembrolizumab was 24%, including 5% of patients with a complete response. Remarkably, 83% of responses were ongoing at the time of analysis, although at a median follow-up duration of response was only 5 months. More responses were reported in the CPS  $\geq$  10% than in the CPS  $<$  10% population (37% vs 18%) [24] (Table 2). The median reported survival with pembrolizumab was of 11.5 months. Median duration of response was remarkable with both agents. Based on these results, both atezolizumab and pembrolizumab were approved for front-line use in cisplatin-ineligible patients with locally advanced or metastatic UC on the basis of the aforementioned studies [24,25], in which outcomes were compared with historical controls [45]. These approvals were conditional and

required confirmatory data from KEYNOTE-361 (NCT02853305) and IMvigor130 (NCT02807636) studies to maintain their approval in this disease state. The data monitoring committees of both first-line trials in treatment-naïve patients identified early deaths among PD-L1<sup>low</sup> populations and decreased survival in the monotherapy arms of both trials. Patients with PD-L1<sup>low</sup> status had decreased survival compared to patients who received cisplatin- or carboplatin-based therapy. Both trials stopped enrollment of patients with PD-L1<sup>low</sup> into the monotherapy arms. First EMA and then the FDA announced their recommendation to restrict the use of atezolizumab and pembrolizumab to PD-L1 high first-line cisplatin-ineligible patients with advanced UC. The updated labels of atezolizumab and pembrolizumab reflect the restricted indications and limit their use to patients with locally advanced or metastatic UC who are not eligible for cisplatin-containing therapy and whose tumors express PD-L1 (CPS  $\geq$  10%) in the case of pembrolizumab and a PD-L1 expression of  $\geq$  5% on tumor-infiltrating immune cells in the case of atezolizumab, or to patients who are ineligible for any platinum-containing chemotherapy regardless of PD-L1 status (FDA only). Several trials are underway to determine optimal first-line therapy for this population (Fig. 2).

### **Immune checkpoint inhibitors as second-line therapy**

Atezolizumab was approved by the FDA in May 2016 for the treatment of locally advanced or metastatic UC that has progressed during or after platinum-based chemotherapy [54,55] after unprecedented quality of responses and outcome being observed in some patients. Its approval was granted based on results from a phase II trial (IMvigor 210) in 311 patients with locally advanced or metastatic bladder cancer refractory to platinum-based chemotherapy. The ORR was 15% at a median follow-up of 11.7 months, and the drug had a manageable safety profile [17]. The most common treatment-related adverse events (TRAEs) were fatigue (52% all

grades, 6% grade 3 or 4), diminished appetite (26% overall, 1% grade 3 or 4), nausea (25% overall, 2% grade 3 or 4), increased risk of urinary tract infection (22% overall, 9% grade 3 or 4), and abdominal pain (17% overall, 4% grade 3 or 4) [54]. Grade 3 and 4 adverse events developed in < 10% of patients [54]. In patients with high levels of PD-L1 expression (> 5% of tumor-infiltrating lymphocytes expressing PD-L1 as determined by immunohistochemistry), the ORR was even higher (27%) and OS duration was longer [17]. In post-hoc analysis, patients whose tumors had a high TML and a TCGA luminal cluster II molecular subtype (n = 50) experienced the best outcomes, while the lowest response rate was observed in tumors with cluster III molecular subtype (n = 38).

Clinical activity was markedly higher than that seen with most systemic chemotherapies (ORR ~ 10%), making PD-L1 inhibition the first improvement on existing standard-of-care second-line therapies [20]. Subsequently, the safety and efficacy of atezolizumab (anti-PD-L1 antibody) vs chemotherapy (docetaxel, paclitaxel, or vinflunine) were assessed in phase III trial (IMvigor211) in 931 patients with metastatic UC who had failed platinum-based chemotherapy. A hierarchical statistical design established survival in patients with PD-L1 expression on  $\geq 5\%$  of tumor-infiltrating immune cells, as the main end-point. OS did not differ between treatment arms (stratified HR: 0.87; 95% CI: 0.63–1.21) in these selected patients with PD-L1 positivity. Despite this trial being negative as per trial design, exploratory analysis in the ITT population showed durable responses and survival benefit for atezolizumab [56]. There were fewer grade 3–4 TRAEs in the atezolizumab arm (20%) than in the chemotherapy arm (43%).

A very recent analysis of the IMvigor 210 trials involving patients with platinum-refractory or cisplatin-ineligible UC who were treated with atezolizumab identified a resistance



signature as an immune biomarker [57]. Investigators described a novel single-patient classifier based on The Cancer Genome Atlas 2017 scheme that identified the neuronal subtype of UC as an extreme responder to anti-PD-L1 therapy.

Pembrolizumab was approved by the FDA in May 2017 for patients with locally advanced or metastatic UC whose disease progressed during or after platinum-containing chemotherapy. This approval was based on the results of KEYNOTE-045 [20], a phase III trial in 542 patients with platinum-refractory advanced UC randomly assigned to receive pembrolizumab or the investigator's choice of chemotherapy (paclitaxel, docetaxel, vinflunine). Patients in the pembrolizumab cohort had a higher ORR (21.1% vs 11.4%). Although patients in the chemotherapy arm of the trial had a slightly longer median PFS, analysis of the main end-point in the intention-to-treat population revealed, that pembrolizumab improved OS compared with chemotherapy in a statistically significant way (10.3 vs 7.4 months;  $P < 0.01$ ), resulting in a 27% reduction in risk of death. Furthermore, 43.9% of patients receiving pembrolizumab were still alive after a year, compared with 31% of those given the existing standard of care. The OS benefit of pembrolizumab over chemotherapy seemed to be independent of PD-L1 expression using the  $> 10\%$  CPS score [20]. Pembrolizumab was also better tolerated than chemotherapy, with fewer TRAEs of any grade (60.9% vs 90.2%) and grade 3–5 TRAEs (15% vs 49.4%). As expected, immune-related adverse events (irAEs) were more common with pembrolizumab than with chemotherapy. An association between treatment with ICIs and good quality of life is increasingly expected; pembrolizumab also proved superior to chemotherapy for this endpoint [58]. The study's independent data monitoring committee recommended that the trial be stopped early after it met the co-primary endpoint for OS [20]. Long-term follow-up data presented at the 2018 ASCO GU Annual Meeting showed that

survival benefit was maintained at 24 months with an HR for death of 0.70 (95% CI: 0.57–0.86;  $P = 0.0004$ ) [59].

The efficacy and safety of nivolumab in metastatic UC were initially reported in the nonrandomized CheckMate 032 study in which nivolumab treatment was associated with a significant ORR of 24.4 % and durable clinical responses in 78 patients with platinum-refractory locally advanced or metastatic UC [60]. In this study, patient response did not seem to be influenced by PD-L1 expression on tumor cells. [59] The larger single-arm, phase II CheckMate 275 study enrolled 270 patients with locally advanced, unresectable or metastatic disease that had progressed despite prior platinum-based therapy and treated them with nivolumab. ORR was again the primary endpoint. At 7.0 months median follow-up, ORR was 19.6% for the whole population and 28.4% for patients whose tumors had PD-L1 expression of  $\geq 5\%$  [21]. Nivolumab had an acceptable safety profile. Correlative studies showed that patients with TCGA cluster III type histology ( $n = 23$ ) had the highest rates of complete response, total objective response, and stable disease when treated with nivolumab. Responders to nivolumab also had tumors enriched for a 25-gene IFN- $\gamma$  signature [21]. By contrast, no complete responses were found in patients who had the cluster IV subtype ( $n = 33$ ). ORR was the lowest and rate of progressive disease was the highest in this tumor subtype. An analysis of TML in 139 patients in this study showed a significant correlation between higher TML and higher response rate, PFS, and OS when adjusted for baseline tumor PD-L1 expression and other clinical and laboratory parameters [27]. The favorable results of the CheckMate 275 study led to accelerated FDA approval of this drug for the treatment of patients with locally advanced or metastatic UC whose disease progressed during or following platinum-based chemotherapy [21,61].

In a phase I/II multicenter, open-label study (n = 191), durvalumab demonstrated meaningful clinical activity in platinum-refractory UC patients. The ORR was 17.8% (95% CI: 12.7%, 24.0%) including seven complete responses in all evaluable patients. Responses were observed regardless of the PD-L1 expression. At the time of data cut-off, median OS was 18.2 months (95% CI: 8.1 months, not estimable). Durvalumab's safety profile was acceptable in this patient population [62,63]. Based on these promising results, the FDA has granted an accelerated approval to the PD-L1 inhibitor durvalumab for the treatment of patients with locally advanced or metastatic UC who have disease progression during or following platinum-containing chemotherapy, or who have disease progression within 12 months of neoadjuvant or adjuvant treatment with platinum-containing chemotherapy [22].

Durvalumab is also under investigation in the DANUBE trial, a randomized, open-label, multicenter, global phase III study assessing durvalumab ± tremelimumab (a CTLA-4 IgG2-kappa monoclonal antibody) vs standard-of-care chemotherapy in treatment-naïve patients with unresectable and/or metastatic UC [64].

In May 2017, the FDA also granted accelerated approval for the use of avelumab in the second-line setting based on the JAVELIN study. In this phase Ib, single arm study, patients treated with avelumab demonstrated clinical activity with durable responses regardless of PD-L1 tumor expression [23,65]. In contrast to other therapies targeting PD-L1 or PD-1, in vitro studies have shown that avelumab prompts antibody-dependent cell-mediated cytotoxicity, resulting in lysis of tumor cells [66]. Contribution of natural killer cells to the antitumor mechanism via antibody-dependent cell-mediated cytotoxicity may contribute to the antitumor activity of avelumab, but this has not yet been demonstrated in clinical trials [23].

As a result of these trials, 5 ICIs are now treatment options for metastatic UC after chemotherapy failure. Naturally, clinicians make informal inter-trial comparisons, with an inherent risk of overinterpretation of the data. Thus, when making treatment decisions, clinicians would be wise to consider the results of 2 phase III trials comparing pembrolizumab and atezolizumab separately with physician's choice of chemotherapy (docetaxel, paclitaxel, or vinflunine), with level 1 evidence favoring the use of pembrolizumab [20,56].

With greater use of ICIs, irAEs present a considerable challenge for patients undergoing therapy. Available data suggest that ICIs induce their off-target effects through several mechanisms, including direct binding to cell-surface proteins expressed in healthy tissue, activation of T cells that cross-react with off-target tissues, generation of autoantibodies, or increased levels of pro-inflammatory cytokines [67]. These irAEs can affect a variety of organs and can result in substantial morbidity and even mortality. Overall, any grade irAE occurs in roughly one quarter of patients treated with ICI while grade 3–4 irAEs are noted in approximately 15% of patients [68]. It is vital that oncologists become familiar with the complications of treatment with immunotherapy [69].

### **Combination immunotherapies**

Despite the success of ICI monotherapy, long-term durable response rates remain low, and most patients relapse. Emerging evidence advocating the immunogenic potential of, for example, chemotherapy have led to the theory that cytotoxic therapy could synergize with ICIs [70,71]. Additionally, cytotoxic therapy could reduce immunosuppressive factors released by tumors or promote antigens presentation, broadening the antitumor T cell response. Early efforts to combine ICIs with traditional chemotherapy had a minimal impact on clinical activity. The combination of GC with ipilimumab did not appear to have a greater impact on survival than

chemotherapy alone [72]. Although ipilimumab did appear to affect the immune system by increasing levels of circulating CD4 and CD8 T cells, the rate of immune-mediated toxicities appeared lower than what was typically observed with this dose of ipilimumab. This observation raised concerns that traditional chemotherapy might not be a feasible foundation for combination with immunotherapy. However, many ongoing clinical trials are exploring the impact of combining systemic chemotherapy with ICIs for the treatment of metastatic UC.

IMvigor 130 is a Phase III trial designed to evaluate the efficacy and safety of first-line atezolizumab given alone or in combination with platinum-based chemotherapy versus platinum-based chemotherapy alone. (NCT02807636) Across 35 countries, this study is enrolling approximately 1200 patients who are treatment-naïve for advanced or metastatic UC [73]. The primary endpoints are PFS, OS and adverse events rate. KEYNOTE-361 is a randomized, open-label, phase III study of pembrolizumab with or without chemotherapy versus chemotherapy alone in patients with advanced UC who have not receive systemic therapy for metastatic disease or have recurred more than 12 months after neoadjuvant chemotherapy (NCT02853305). Patients are being randomly assigned 1:1:1 to receive single-agent pembrolizumab, pembrolizumab plus investigator's choice of chemotherapy (GC) or chemotherapy alone. Cisplatin-ineligible patients randomly assigned to chemotherapy will receive gemcitabine plus carboplatin. Primary endpoints are PFS and OS; secondary end points include ORR rate and safety and tolerability. The NILE trial is a randomized, open-label, controlled, multi-center, phase III study to determine the efficacy and safety of as first-line combining durvalumab with or without tremelimumab with standard of care chemotherapy (cisplatin + gemcitabine or carboplatin + gemcitabine doublet) followed by durvalumab monotherapy versus standard of care alone as first-line chemotherapy

for advanced or metastatic UC. Primary endpoint is OS. (NCT03682068) The magnitude of the overall survival benefit of such regimens will determine their future use.

Treatment strategies that combine PD-1/PD-L1 inhibitors and an anti-CTLA-4 antibody have the potential for increased antitumor activity. From a mechanistic perspective, this finding is consistent with the contrasting role of PD-1 in regulating the effector phase of the immune response, as opposed to the role of CTLA-4 in mediating the priming phase. In the CheckMate 032 study, phase I/II trial, patients who progressed after platinum-based chemotherapy received either nivolumab or 1 of 2 combinations of nivolumab plus ipilimumab [74]. The combination of a 1-mg/kg infusion of nivolumab and a 3-mg/kg infusion of ipilimumab yielded a 38.5% ORR, including a 4% complete response rate, whereas the combination of 3 mg/kg of nivolumab and 1 mg/kg of ipilimumab yielded a 26% ORR and a 3% complete response rate. Importantly, clinical activity seemed to be improved with higher doses of ipilimumab. Treatment with single-agent nivolumab resulted in a 24.4% ORR and a 6% complete response rate [74]. The spectrum and incidence of TRAEs was consistent with those noted in prior trials. Longer follow-up results of CheckMate 032 showed that [75] higher dose of ipilimumab was associated with increased antitumor activity while maintaining an acceptable toxicity profile. The combination of a 1-mg/kg infusion of nivolumab and a 3-mg/kg infusion of ipilimumab showed an approximately 12% higher response rate, and the duration of response appeared longer. A trend toward higher response rate and longer median PFS and OS compared to previous reports of PD-1 and PD-L1 monotherapies was also observed with the higher dose of ipilimumab in the PD-L1 unselected patient population [75]. Although data on OS are still premature for this arm, if they are confirmed in an ongoing phase III randomized trial (CheckMate 901; NCT03036098), the combination of a 1-mg/kg infusion of nivolumab and a 3-mg/kg infusion of ipilimumab would be

avored over other dosages. The question has arisen as to whether concurrent ipilimumab and nivolumab offers benefit that could not be gained with sequential single-agent anti-PD-1 and anti-CTLA-4 therapy. This concept is currently being tested in a randomized phase II trial of durvalumab alone or in combination with tremelimumab (anti-CTLA-4) vs their sequential use (NCT02527434). Ultimately, further work is required to establish the optimal dose and schedule of ICIs for priming an antitumor T-cell response in patients with bladder cancer in order to inform the design of further clinical trials.

Tumors proliferate by activating proangiogenic pathways and simultaneously suppressing the immune response by upregulating immune checkpoint pathways. Accumulating evidence suggests that tumorigenesis requires dual regulation of neoangiogenesis and immunosuppression, leading to the hypothesis that targeting both processes simultaneously may facilitate the synergistic increase of antitumor immune function [76]. Thus, from the clinical perspective, the potential role of combination regimens containing antiangiogenic therapy and ICIs is of considerable interest. Initial results from a study of ICIs with vascular endothelial growth factor inhibitors are discussed in the next section.

### **Antiangiogenic therapy**

VEGFR 1 and 2 and their ligands (VEGF-A, -B, -C, and -D) are important mediators of tumor angiogenesis and seem to contribute to the pathogenesis and progression of UC [77]. Multiple agents targeting the VEGF pathway have been investigated as single agents or in randomized trials combining VEGF/VEGFR inhibitors with traditional chemotherapy [78-85]. Several single-arm studies have investigated the use of single-agent sorafenib, pazopanib and sunitinib, with limited clinical activity [83,86-90]. Sunitinib has also been studied in

combination with GC, where it led to excessive hematologic toxicity [91]. In the same direction, the addition of vandetanib to docetaxel does not result in significantly improved clinical activity in patients with platinum-pretreated metastatic UC [78]. The toxicity of vandetanib plus docetaxel was greater than for vandetanib plus placebo. In the same trial, single-agent vandetanib activity was minimal [78]. Single-agent pazopanib has demonstrated modest clinical activity in unselected relapsed/refractory metastatic UC [91-92] and did not show greater efficacy than paclitaxel in the second-line treatment of metastatic UC [92]. Similarly, cabozantinib, a tyrosine kinase inhibitor that primarily targets c-MET, VEGFR2 and RET, showed clinical activity in a phase II study with an encouraging ORR of 19.5% in patients with relapsed or refractory metastatic UC. However, the median PFS with cabozantinib was only 3.7 months (95% CI: 2.3–6.5) [93]. Cabozantinib is currently in combination clinical trials with ICIs (NCT02496208). The safety and efficacy of cabozantinib was evaluated in a phase I study of nivolumab with or without ipilimumab. This study included a phase I cohort and several expansion cohorts of patients including one of refractory metastatic UC. [94,95]. Significant clinical activity in the refractory metastatic UC population was observed, with an ORR of 33% for cabozantinib plus nivolumab and 51% for the triple combination. The median duration of response for the entire cohort of UC patients was 24 months (95% CI: 14.7–undefined) [96].

Bevacizumab, a monoclonal antibody directed against circulating VEGF, has shown encouraging clinical activity in UC. A phase II trial of GC and bevacizumab as first-line therapy for metastatic UC showed an ORR of 72% and an encouraging OS of 19.1 months (95% CI: 12.4–22.7 months) [85]. This promising regimen has been evaluated in a phase III clinical trial that randomized patients to standard treatment with GC with or without bevacizumab (NCT00942331). We are eagerly awaiting the results of this trial.



After many trials demonstrating modest activity with antiangiogenic therapies for UC, this therapeutic strategy may have found redemption with a tolerable combination of ramucirumab and chemotherapy. A recent randomized phase II study by Petrylak, et al. randomized patients with platinum-pretreated locally advanced or metastatic UC 1:1:1 to receive docetaxel alone vs docetaxel plus ramucirumab or icrucumab [97]. Although this study failed to meet its primary endpoint, the addition of ramucirumab to docetaxel demonstrated prolonged PFS (5.4 vs 2.8 months;  $P = 0.0002$ ) [97]. In 2018, the subsequent phase III trial by Petrylak et al. confirmed longer PFS with ramucirumab plus docetaxel, consistent with the earlier report. The ramucirumab-plus-docetaxel arm had a PFS of 4.07 months versus 2.76 months in the docetaxel-alone arm (HR: 0.69; 95% CI: 0.573–0.845;  $P = 0.0002$ ). Unfortunately, ramucirumab plus docetaxel did not demonstrate an OS benefit compared to single-agent docetaxel [84]. In the same line, one of the most encouraging results came from a recently conducted phase II trial of paclitaxel plus pazopanib that resulted in a substantial ORR of 54% in patients with advanced pretreated UC [98].

### **ErbB therapy**

The ErbB family, consisting of EGFR, HER2, ErbB3, and ErbB4, is a class of receptor tyrosine kinases that has been extensively investigated as potentially important in the pathogenesis of UC. EGFR overexpression in UC is associated with higher tumor grade and muscle invasiveness, tumor recurrence and overall survival. Similarly [99], HER2 overexpression in UC is correlated with recurrence and metastasis [100]. A comprehensive molecular analysis has also shown that EGFR amplifications (11%), HER2 amplifications (7%), and ErbB3 somatic mutations (11%) are relatively frequent in UC [7,101]. Earlier clinical data

on EGFR and HER2 inhibition in UC was discouraging, with two negative trials for gefitinib in chemotherapy-resistant metastatic UC [102,103]. A phase II trial testing trastuzumab in a combination regimen in HER2-positive UC had a 70% response rate but higher-than-expected rates of cardiotoxicity [104].

The efficacy of combinatory regimens such as GC with or without cetuximab (anti-EGFR monoclonal antibody) in unselected advanced UC has been evaluated. In a phase II trial, patients were randomized 1:2 to receive GC alone or with cetuximab. This study did not demonstrate additional activity with the combination but did report increased toxicity, with higher-than-expected rates of thromboembolism resulting in treatment discontinuation [105]. Separately, patients with previously treated metastatic UC whose tumors had 2+ or 3+ expression levels of EGFR or HER2 had prolonged survival when treated with lapatinib compared with those with 0/1+ expression, suggesting a potential role for dual inhibition in patients with HER2/EGFR overexpression [106].

Afatinib demonstrated significant activity in patients with platinum-refractory metastatic UC with HER2 or ErbB3 alterations. Eighty-three percent of patients with HER2 and/or ErbB3 alterations achieved 3-month PFS endpoint (PFS = 10.3, 7.0, 6.9, 6.3, and 5.0 months, respectively) vs 0/15 patients without alterations [107]. An ongoing phase II trial is evaluating afatinib in patients with metastatic UC molecularly selected for ErbB receptor alterations – ErbB2/ErbB3 mutations or ErbB2 amplification in Cohort A, or EGFR (ErbB1) amplification Cohort B (NCT02780687).

### **FGFR therapy**

Although *FGFR* alterations are more frequent in non-MIBC, they are found in up to 21% of locally advanced or metastatic UC, with amplifications, mutations, and fusions in *FGFR* gene. Alterations in *FGFR3* gene are enriched in the TCGA luminal 1 subtype of UC. Initial efforts to inhibit FGFRs in clinical trials were with multi-tyrosine kinase inhibitors. Dovitinib was investigated in a phase II trial of patients with advanced UC who received prior platinum-containing chemotherapy. No responses were seen in the *FGFR3*-mutated population, and only one response was seen in the wild-type group. Thus, the trial was terminated at the end of stage 1 for lack of efficacy [108].

However, antitumor activity observed in patients with metastatic UC in a phase 1 trial of the *FGFR* 1-3 inhibitor, BGJ398 (NCT01004224) led to initiation of an extended cohort of genetically selected patients to further characterize its activity in such a population. Treatment with various doses of BGJ398 resulted in disease control in 42 of 132 patients, including 3 partial responses in metastatic patients with *FGFR3*-mutated UC [109]. This outcome represented a 38% response rate and a 75% disease control rate in UCs with *FGFR3* alterations and led to the opening of a new trial arm to investigate the efficacy of BGJ398 specifically in this patient population [110].

Early results with erdafitinib demonstrated durable responses in 3 patients with UC, one with *FGFR3* translocation and another with *FGFR2* truncation. The tolerability of this drug has allowed for continuous dosing with up-titration on the basis of phosphorus level. Results of an open-label phase II study of erdafitinib were reported in 2018, showing a promising ORR rate of 42% (3% complete responses, 39% partial responses) and an 80% disease control rate in patients with chemorefractory metastatic UC and *FGFR* alterations. The median PFS was 5.5 months and the median OS was 13.8 months. There was a very impressive clinical ORR of 70% among

patients previously treated with ICIs, a population with poor prognosis and high unmet need [19].

AZD4547, another orally available FGFR inhibitor, has also demonstrated durable responses in 2/3 patients, both harboring high FGFR1 and FGFR3 expression. The third patient had a mutation in the ligand-binding domain of *FGFR3* [111]. Meanwhile, phase I results from the Debio 1347 trial of this highly selective pan-FGFR inhibitor included partial responses in 5 patients out of 56 treated; one responding patient had UC with FGFR3 fusion [112]. In patients with high FGFR1–3 tumor messenger RNA levels, rogaratinib (BAY 1163877) showed the highest ORR in the bladder cancer expansion cohort, with 3 partial responses out of 8 patients treated [113]. In contrast, TAS-120, a highly selective covalent oral FGFR inhibitor, produced no measurable responses in 8 patients with UCs [114].

Another strategy is to target FGFR with monoclonal antibodies. A phase I trial with MFGR1877S, an FGFR3-specific monoclonal antibody, enrolled 10 patients with advanced UC [115]. Long-term stable disease was observed in 5 patients. B-701 is another monoclonal antibody that blocks both wild-type and activated mutant FGFR3 receptors. Early investigations with B-701 were in combination with docetaxel for patients with disease progression on or after 1 or 2 lines of prior chemotherapy, excluding taxanes. In a preliminary report, of 17 evaluable patients, one experienced a complete response, 2 experienced a partial response, and a 58% disease control rate was observed [116]. Five patients, including the 2 with objective responses, had *FGFR3* mutations. A trial of B-701 in combination with pembrolizumab for platinum-experienced UC patients is underway (NCT03123055).

The most common treatment-emergent toxicities with FGFR inhibitors are hyperphosphatemia, stomatitis, diarrhea, elevated creatinine, fatigue, hand-foot syndrome and decreased appetite.

Updated guidelines that support implementation of molecular testing in patients with UC would provide information about mutational spectrum of UC, facilitate the participation of patients in prospective FGFR inhibitors trials and predict the emergence of resistance.

### **Antibody-drug conjugates**

Antibody-drug conjugates are characterized by a monoclonal antibody against a highly expressed cancer cell target, with a protease-cleavable linker bound to a cytotoxic agent. The chemotherapeutic agent is only released internally in select cells expressing the protein target after internalization of the antibody-drug conjugate and lysosomal cleavage. In recent trials in UC, an antibody linked to the microtubule-disrupting agent monomethyl auristatin E has shown reasonable clinical activity. The antibody-drug conjugate ASG-15ME is targeted to SLITRK6, a type I transmembrane neuronal receptor. SLITRK6 expression is identified by IHC in 90% of UCs [117]. In a phase I trial of heavily pretreated patients with metastatic UC, 1 mg/kg was identified as the maximum tolerated dose of ASG-15ME. Toxicity with this agent was predictable, with reversible ocular TRAEs occurring in 29.4% of patients. Among the 51 patients across all dosing levels, there were 17 partial responses and 1 complete response, for a 37.5% ORR [118]. However, unique subgroups showed impressive results, with an ORR of 50% at the maximum tolerated dose, 53% in ICI-treated patients, and 46% in patients with liver metastases.

Another antibody-drug conjugate with promising phase I results is enfortumab vedotin (ASG-22ME), which is composed of an anti-nectin-4 monoclonal antibody attached to monomethyl auristatin E, a microtubule-disrupting agent. This agent targets nectin-4, a cell adhesion molecule that is highly expressed in multiple cancers, including UC [119]. The FDA has granted enfortumab vedotin a breakthrough therapy designation for patients with locally advanced or metastatic UC who previously received immune checkpoint therapy. This was based on interim results from a phase I dose-escalation/dose-expansion trial evaluating enfortumab vedotin monotherapy in patients with metastatic UC and other solid tumors. Data from the cohort of metastatic UC showed that enfortumab vedotin has an ORR of 41% among 71 evaluable patients. Ninety-five percent of patients had prior platinum-based therapy, 46% had received a ICIs, and 43% had prior taxane treatment. The ORR at the recommended phase II dose (RP2D) was 53% (NCT02091999). Enfortumab vedotin was well tolerated with grade  $\geq 3$  AEs in the RP2D cohort consistent in urinary tract infection (8%), hypophosphatemia (3%), hyponatremia (5%), anemia (8%), and hyperuricemia (5%). Rosenberg *et al.* provided updated results from 122 patients with previously treated mUC who received enfortumab vedotin at the RP2D at the 2018 ASCO meeting [120]. Confirmed complete response and partial responses were observed in 4% and 37% of patients, respectively, consistent with an ORR of 41%. Additional stable disease was seen in 30% of patients. Although data are still immature as many patients were early in their treatment course, median PFS was 5.4 months and median OS was 13.6 months. There were reported fatal treatment-related adverse event in 4 patients (respiratory failure, urinary tract obstruction, diabetic ketoacidosis, multi-organ failure). With hope for further improvement of these impressive outcomes, a phase I trial (NCT03299545) of enfortumab vedotin in combination with either atezolizumab or pembrolizumab was recently launched.

## Conclusions

Over a relatively short period of time, the number of effective treatment options for patients with advanced UC has increased considerably. The current immunotherapy landscape in metastatic UC is defined by the approved use of 5 ICIs in the second-line setting and the recent approval of pembrolizumab and atezolizumab for platinum-ineligible patients or patients who are not eligible for cisplatin-containing therapy and whose tumors express PD-L1. Patient- and tumor-specific features such as renal function and PD-L1 status should still be high priorities when considering front-line systemic therapy. Although more evidence is needed, dual immunotherapy regimens, alternate combined ICI and targeted therapies, novel FGFR inhibitors and antibody-drug conjugates hold considerable promise for metastatic bladder cancer. In this changing UC therapy paradigm, development and validation of biomarkers that can identify patients who are most likely to benefit from a particular therapy are crucial.

## Acknowledgment

No applicable

## Authors' contribution

The manuscript preparation was done by RN and JB and edited by RN and JB. All authors make substantial contributions to the writing, revising it critically. All authors read and approved the final manuscript.

**References**

- [1] Antoni S, Ferlay J, Soerjomataram I, Znaor A, Jemal A, Bray F. Bladder Cancer Incidence and Mortality: A Global Overview and Recent Trends. *Eur Urol* 2017;71(1):96-108.
- [2] Smith AB, Deal AM, Woods ME, Wallen EM, Pruthi RS, Chen RC, et al. Muscle-invasive bladder cancer: evaluating treatment and survival in the National Cancer Data Base. *BJU Int* 2014;114(5):719-26.
- [3] Burger M, Catto JW, Dalbagni G, Grossman HB, Herr H, Karakiewicz P, et al. Epidemiology and risk factors of urothelial bladder cancer. *Eur Urol* 2013;63(2):234-41.
- [4] Korpai M, Puyang X, Jeremy Wu Z, Seiler R, Furman C, Oo HZ, et al. Evasion of immunosurveillance by genomic alterations of PPARgamma/RXRalpha in bladder cancer. *Nat Commun* 2017;8(1):103.
- [5] Galsky MD, Saci A, Szabo P, Wang L, Zhu J, Azrilevich A, et al. Fibroblast growth factor receptor 3 (FGFR3), peroxisome proliferator-activated receptor gamma (PPARg), and outcomes with nivolumab (nivo) in metastatic urothelial cancer (UC). *J Clin Oncol* 2018;36(6 suppl):511.
- [6] Choi W, Porten S, Kim S, Willis D, Plimack ER, Hoffman-Censits J, et al. Identification of distinct basal and luminal subtypes of muscle-invasive bladder cancer with different sensitivities to frontline chemotherapy. *Cancer Cell* 2014;25(2):152-65.
- [7] Cancer Genome Atlas Research Network. Comprehensive molecular characterization of urothelial bladder carcinoma. *Nature* 2014;507(7492):315-22.
- [8] Robertson AG, Kim J, Al-Ahmadie H, Bellmunt J, Guo G, Cherniack AD, et al. Comprehensive Molecular Characterization of Muscle-Invasive Bladder Cancer. *Cell* 2017;171(3):540-56.e25.
- [9] Kim J, Mouw KW, Polak P, Braunstein LZ, Kamburov A, Kwiatkowski DJ, et al. Somatic ERCC2 mutations are associated with a distinct genomic signature in urothelial tumors. *Nat Genet* 2016;48(6):600-6.
- [10] Roberts SA, Lawrence MS, Klimczak LJ, Grimm SA, Fargo D, Stojanov P, et al. An APOBEC cytidine deaminase mutagenesis pattern is widespread in human cancers. *Nat Genet* 2013;45(9):970-6.
- [11] Sjobahl G, Eriksson P, Liedberg F, Hoglund M. Molecular classification of urothelial carcinoma: global mRNA classification versus tumour-cell phenotype classification. *J Pathol* 2017;242(1):113-25.
- [12] Sonpavde G, Galsky MD, Latini D, Chen GJ. Cisplatin-ineligible and chemotherapy-ineligible patients should be the focus of new drug development in patients with advanced bladder cancer. *Clin Genitourin Cancer* 2014;12(2):71-3.
- [13] Galsky MD, Hahn NM, Rosenberg J, Sonpavde G, Hutson T, Oh WK, et al. Treatment of patients with metastatic urothelial cancer "unfit" for Cisplatin-based chemotherapy. *J Clin Oncol* 2011;29(17):2432-8.
- [14] Abdelhafez M, Williams M. Safety and Efficacy Gemcitabine-Cisplatin Split Dose as a Neoadjuvant Chemotherapy for Muscle Invasive Bladder Cancer. *J Urol* 2017;197(4):e1194.
- [15] Morales-Barrera R, Bellmunt J, Suarez C, Valverde C, Guix M, Serrano C, et al. Cisplatin and gemcitabine administered every two weeks in patients with locally advanced or metastatic urothelial carcinoma and impaired renal function. *Eur J Cancer* 2012;48(12):1816-21.



- [16] Cheng T, Roth B, Choi W, Black PC, Dinney C, McConkey DJ. Fibroblast growth factor receptors-1 and -3 play distinct roles in the regulation of bladder cancer growth and metastasis: implications for therapeutic targeting. *PLoS One* 2013;8(2):e57284.
- [17] Rosenberg JE, Hoffman-Censits J, Powles T, van der Heijden MS, Balar AV, Necchi A, et al. Atezolizumab in patients with locally advanced and metastatic urothelial carcinoma who have progressed following treatment with platinum-based chemotherapy: a single-arm, multicentre, phase 2 trial. *Lancet* 2016;387(10031):1909-20.
- [18] Corrales L, Matson V, Flood B, Spranger S, Gajewski TF. Innate immune signaling and regulation in cancer immunotherapy. *Cell Res* 2017;27(1):96-108.
- [19] Siefker-Radtke A, Necchi A, Park S, Garca-Donas J, Huddart R, Burgess E, et al. First results from the primary analysis population of the phase 2 study of erdafitinib (ERDA; JNJ-42756493) in patients (pts) with metastatic or unresectable urothelial carcinoma (mUC) and FGFR alterations (FGFRalt). *J Clin Oncol* 2018;36(15 suppl):abstr 4503.
- [20] Bellmunt J, de Wit R, Vaughn DJ, Fradet Y, Lee JL, Fong L, et al. Pembrolizumab as Second-Line Therapy for Advanced Urothelial Carcinoma. *N Engl J Med* 2017;376(11):1015-26.
- [21] Sharma P, Retz M, Siefker-Radtke A, Baron A, Necchi A, Bedke J, et al. Nivolumab in metastatic urothelial carcinoma after platinum therapy (CheckMate 275): a multicentre, single-arm, phase 2 trial. *Lancet Oncol* 2017;18(3):312-22.
- [22] IMFINZI: Highlights of Prescribing Information: FDA; 2017 [Available from: [https://www.accessdata.fda.gov/drugsatfda\\_docs/label/2017/761069s000lbl.pdf](https://www.accessdata.fda.gov/drugsatfda_docs/label/2017/761069s000lbl.pdf)].
- [23] Apolo AB, Infante JR, Balmanoukian A, Patel MR, Wang D, Kelly K, et al. Avelumab, an Anti-Programmed Death-Ligand 1 Antibody, In Patients With Refractory Metastatic Urothelial Carcinoma: Results From a Multicenter, Phase Ib Study. *J Clin Oncol* 2017;35(19):2117-24.
- [24] Balar AV, Castellano D, O'Donnell PH, Grivas P, Vuky J, Powles T, et al. First-line pembrolizumab in cisplatin-ineligible patients with locally advanced and unresectable or metastatic urothelial cancer (KEYNOTE-052): a multicentre, single-arm, phase 2 study. *Lancet Oncol* 2017;18(11):1483-92.
- [25] Balar AV, Galsky MD, Rosenberg JE, Powles T, Petrylak DP, Bellmunt J, et al. Atezolizumab as first-line treatment in cisplatin-ineligible patients with locally advanced and metastatic urothelial carcinoma: a single-arm, multicentre, phase 2 trial. *Lancet* 2017;389(10064):67-76.
- [26] Masucci GV, Cesano A, Hawtin R, Janetzki S, Zhang J, Kirsch I, et al. Validation of biomarkers to predict response to immunotherapy in cancer: Volume I - pre-analytical and analytical validation. *J Immunother Cancer* 2016;476.
- [27] Galsky MD, Saci A, Szabo P, Azrilevich A, Horak C, Lambert A, et al. Impact of tumor mutational burden on nivolumab efficacy in second-line urothelial carcinoma patients: exploratory analysis of phase II CHECKMATE 275 study. *Ann Oncol* 2017;28:v295-v329.
- [28] Carlo M, Zhang L, Mandelker D, Vijai J, Cipolla C, Robson M, et al. Cancer predisposing germline mutations in patients (pts) with urothelial cancer (UC) of the renal pelvis (R-P), ureter (U) and bladder (B). *J Clin Oncol* 2017;35(15 suppl):abstr 4510.
- [29] Iyer G, Audenet F, Middha S, Carlo M, Regazzi A, Funt S, et al. Mismatch repair (MMR) detection in urothelial carcinoma (UC) and correlation with immune checkpoint blockade (ICB) response. *J Clin Oncol* 2017;35(15 suppl):abstr 4511.

- [30] Bellmunt J, Paz-Ares L, Cuello M, Cecere FL, Albiol S, Guillem V, et al. Gene expression of ERCC1 as a novel prognostic marker in advanced bladder cancer patients receiving cisplatin-based chemotherapy. *Ann Oncol* 2007;18(3):522-8.
- [31] Urun Y, Leow JJ, Fay AP, Albiges L, Choueiri TK, Bellmunt J. ERCC1 as a prognostic factor for survival in patients with advanced urothelial cancer treated with platinum based chemotherapy: A systematic review and meta-analysis. *Crit Rev Oncol Hematol* 2017;120:120-6.
- [32] Teo MY, Bambrury RM, Zabor EC, Jordan E, Al-Ahmadie H, Boyd ME, et al. DNA Damage Response and Repair Gene Alterations Are Associated with Improved Survival in Patients with Platinum-Treated Advanced Urothelial Carcinoma. *Clin Cancer Res* 2017;23(14):3610-8.
- [33] Sternberg CN, Yagoda A, Scher HI, Watson RC, Geller N, Herr HW, et al. Methotrexate, vinblastine, doxorubicin, and cisplatin for advanced transitional cell carcinoma of the urothelium. Efficacy and patterns of response and relapse. *Cancer* 1989;64(12):2448-58.
- [34] Loehrer PJ, Sr., Einhorn LH, Elson PJ, Crawford ED, Kuebler P, Tannock I, et al. A randomized comparison of cisplatin alone or in combination with methotrexate, vinblastine, and doxorubicin in patients with metastatic urothelial carcinoma: a cooperative group study. *J Clin Oncol* 1992;10(7):1066-73.
- [35] Logothetis CJ, Dexeus FH, Finn L, Sella A, Amato RJ, Ayala AG, et al. A prospective randomized trial comparing MVAC and CISCA chemotherapy for patients with metastatic urothelial tumors. *J Clin Oncol* 1990;8(6):1050-5.
- [36] von der Maase H, Andersen L, Crino L, Weinknecht S, Dogliotti L. Weekly gemcitabine and cisplatin combination therapy in patients with transitional cell carcinoma of the urothelium: a phase II clinical trial. *Ann Oncol* 1999;10(12):1461-5.
- [37] Moore MJ, Winquist EW, Murray N, Tannock IF, Huan S, Bennett K, et al. Gemcitabine plus cisplatin, an active regimen in advanced urothelial cancer: a phase II trial of the National Cancer Institute of Canada Clinical Trials Group. *J Clin Oncol* 1999;17(9):2876-81.
- [38] Kaufman D, Raghavan D, Carducci M, Levine EG, Murphy B, Aisner J, et al. Phase II trial of gemcitabine plus cisplatin in patients with metastatic urothelial cancer. *J Clin Oncol* 2000;18(9):1921-7.
- [39] von der Maase H, Hansen SW, Roberts JT, Dogliotti L, Oliver T, Moore MJ, et al. Gemcitabine and cisplatin versus methotrexate, vinblastine, doxorubicin, and cisplatin in advanced or metastatic bladder cancer: results of a large, randomized, multinational, multicenter, phase III study. *J Clin Oncol* 2000;18(17):3068-77.
- [40] von der Maase H, Sengelov L, Roberts JT, Ricci S, Dogliotti L, Oliver T, et al. Long-term survival results of a randomized trial comparing gemcitabine plus cisplatin, with methotrexate, vinblastine, doxorubicin, plus cisplatin in patients with bladder cancer. *J Clin Oncol* 2005;23(21):4602-8.
- [41] Sternberg CN, de Mulder P, Schornagel JH, Theodore C, Fossa SD, van Oosterom AT, et al. Seven year update of an EORTC phase III trial of high-dose intensity M-VAC chemotherapy and G-CSF versus classic M-VAC in advanced urothelial tract tumours. *Eur J Cancer* 2006;42(1):50-4.
- [42] Bamias A, Karadimou A, Lampaki S, Aravantiinos G, Xanthakis I, Papandreou C, et al. Prospective, randomized Phase III study comparing two intensified regimens (methotrexate/vinblastine/doxorubicin hydrochloride/cisplatin (MVAC) vs gemcitabine/cisplatin) in patients with inoperable or recurrent urothelial cancer. *J Clin Oncol* 2011;29(15 suppl):abstr 4510.

- [43] Bellmunt J, von der Maase H, Mead GM, Skoneczna I, De Santis M, Daugaard G, et al. Randomized phase III study comparing paclitaxel/cisplatin/gemcitabine and gemcitabine/cisplatin in patients with locally advanced or metastatic urothelial cancer without prior systemic therapy: EORTC Intergroup Study 30987. *J Clin Oncol* 2012;30(10):1107-13.
- [44] Sternberg CN, Skoneczna IA, Castellano D, Theodore C, Blais N, Voog E, et al. Larotaxel with Cisplatin in the first-line treatment of locally advanced/metastatic urothelial tract or bladder cancer: a randomized, active-controlled, phase III trial (CILAB). *Oncology* 2013;85(4):208-15.
- [45] De Santis M, Bellmunt J, Mead G, Kerst JM, Leahy M, Maroto P, et al. Randomized phase II/III trial assessing gemcitabine/carboplatin and methotrexate/carboplatin/vinblastine in patients with advanced urothelial cancer who are unfit for cisplatin-based chemotherapy: EORTC study 30986. *J Clin Oncol* 2012;30(2):191-9.
- [46] De Santis M, Wiechno PJ, Bellmunt J, Lucas C, Su WC, Albiges L, et al. Vinflunine-gemcitabine versus vinflunine-carboplatin as first-line chemotherapy in cisplatin-unfit patients with advanced urothelial carcinoma: results of an international randomized phase II trial (JASINT1). *Ann Oncol* 2016;27(3):449-54.
- [47] Pronzato P, Viganì A, Pensa F, Vanoli M, Tani F, Vaira F. Second line chemotherapy with ifosfamide as outpatient treatment for advanced bladder cancer. *Am J Clin Oncol* 1997;20(5):519-21.
- [48] Lorusso V, Pollera CF, Antimi M, Luporini G, Gridelli C, Frassinetti GL, et al. A phase II study of gemcitabine in patients with transitional cell carcinoma of the urinary tract previously treated with platinum. Italian Co-operative Group on Bladder Cancer. *Eur J Cancer* 1998;34(8):1208-12.
- [49] Sridhar SS, Canil C, Mukherjee SD, Winquist E, Elser C, Eisen A, et al. A phase II study of single-agent nab-paclitaxel as second-line therapy in patients with metastatic urothelial carcinoma. *J Clin Oncol* 2010;28(15 suppl):abstr TPS231.
- [50] Vaughn DJ, Broome CM, Hussain M, Gutheil JC, Markowitz AB. Phase II trial of weekly paclitaxel in patients with previously treated advanced urothelial cancer. *J Clin Oncol* 2002;20(4):937-40.
- [51] Papamichael D, Gallagher CJ, Oliver RT, Johnson PW, Waxman J. Phase II study of paclitaxel in pretreated patients with locally advanced/metastatic cancer of the bladder and ureter. *Br J Cancer* 1997;75(4):606-7.
- [52] McCaffrey JA, Hilton S, Mazumdar M, Sadan S, Kelly WK, Scher HI, et al. Phase II trial of docetaxel in patients with advanced or metastatic transitional-cell carcinoma. *J Clin Oncol* 1997;15(5):1853-7.
- [53] Bellmunt J, Theodore C, Demkov T, Komyakov B, Sengelov L, Daugaard G, et al. Phase III trial of vinflunine plus best supportive care compared with best supportive care alone after a platinum-containing regimen in patients with advanced transitional cell carcinoma of the urothelial tract. *J Clin Oncol* 2009;27(27):4454-61.
- [54] Markham A. Atezolizumab: First Global Approval. *Drugs* 2016;76(12):1227-32.
- [55] Ratner M. Genentech's PD-L1 agent approved for bladder cancer. *Nat Biotechnol* 2016;34(8):789-90.
- [56] Powles T, Duran I, van der Heijden MS, Loriot Y, Vogelzang NJ, De Giorgi U, et al. Atezolizumab versus chemotherapy in patients with platinum-treated locally advanced or metastatic urothelial carcinoma (IMvigor211): a multicentre, open-label, phase 3 randomised controlled trial. *Lancet* 2018;391(10122):748-57.

- [57] Kim J, Kwiatkowski D, McConkey DJ, Meeks JJ, Freeman SS, Bellmunt J, et al. The Cancer Genome Atlas Expression Subtypes Stratify Response to Checkpoint Inhibition in Advanced Urothelial Cancer and Identify a Subset of Patients with High Survival Probability. *Eur Urol* 2019.
- [58] Vaughn DJ, Bellmunt J, de Wit R, Fradet Y, Lee J, Fong L, et al. Health-related quality of life (HRQoL) in the KEYNOTE-045 study of pembrolizumab versus investigator-choice chemotherapy for previously treated advanced urothelial cancer. *J Clin Oncol* 2017;35(6 suppl):abstr 282.
- [59] Bellmunt J, De Wit R, Vaughn DJ, Fradet Y, Lee J, Fong L, et al. Two-year follow-up from the phase 3 KEYNOTE-045 trial of pembrolizumab (pembro) vs investigator's choice (paclitaxel, docetaxel, or vinflunine) in recurrent, advanced urothelial cancer (UC). *J Clin Oncol* 2018;36(6 suppl):abstr 410.
- [60] Sharma P, Callahan MK, Bono P, Kim J, Spiliopoulou P, Calvo E, et al. Nivolumab monotherapy in recurrent metastatic urothelial carcinoma (CheckMate 032): a multicentre, open-label, two-stage, multi-arm, phase 1/2 trial. *Lancet Oncol* 2016;17(11):1590-8.
- [61] OPDIVO: Highlights of Prescribing Information: FDA; 2014 [Available from: [https://packageinserts.bms.com/pi/pi\\_opdivo.pdf](https://packageinserts.bms.com/pi/pi_opdivo.pdf)].
- [62] Massard C, Gordon MS, Sharma S, Rafii S, Wainberg ZA, Luke J, et al. Safety and Efficacy of Durvalumab (MEDI4736), an Anti-Programmed Cell Death Ligand-1 Immune Checkpoint Inhibitor, in Patients With Advanced Urothelial Bladder Cancer. *J Clin Oncol* 2016;34(26):3119-25.
- [63] Powles T, O'Donnell PH, Massard C, Arkenau HT, Friedlander TW, Hoimes CJ, et al. Efficacy and Safety of Durvalumab in Locally Advanced or Metastatic Urothelial Carcinoma: Updated Results From a Phase 1/2 Open-label Study. *JAMA Oncol* 2017;3(9):e172411.
- [64] Powles T, Galsky MD, Castellano D, van der Heijden MS, Petrylak DP, Armstrong J, et al. A phase 3 study of first-line durvalumab (MEDI4736) ± tremelimumab versus standard of care (SoC) chemotherapy (CT) in patients (pts) with unresectable Stage IV urothelial bladder cancer (UBC): DANUBE. *J Clin Oncol* 2016;34(15 suppl):abstr TPS4574.
- [65] Patel MR, Ellerton J, Agrawal M, Gordon MS, Dirix L, Lee K, et al. Avelumab (MSB0010718C; anti-PD-L1) in patients with metastatic urothelial carcinoma progressed after platinum-based therapy or platinum ineligible. *Ann Oncol* 2016;27(6 suppl):777PD.
- [66] Boyerinas B, Jochems C, Fantini M, Heery CR, Gulley JL, Tsang KY, et al. Antibody-Dependent Cellular Cytotoxicity Activity of a Novel Anti-PD-L1 Antibody Avelumab (MSB0010718C) on Human Tumor Cells. *Cancer Immunol Res* 2015;3(10):1148-57.
- [67] Sury K, Perazella MA, Shirali AC. Cardiorenal complications of immune checkpoint inhibitors. *Nat Rev Nephrol* 2018;14(9):571-88.
- [68] Maughan BL, Bailey E, Gill DM, Agarwal N. Incidence of Immune-Related Adverse Events with Program Death Receptor-1- and Program Death Receptor-1 Ligand-Directed Therapies in Genitourinary Cancers. *Front Oncol* 2017;7:56.
- [69] Boutros C, Tarhini A, Routier E, Lambotte O, Ladurie FL, Carbonnel F, et al. Safety profiles of anti-CTLA-4 and anti-PD-1 antibodies alone and in combination. *Nat Rev Clin Oncol* 2016;13(8):473-86.
- [70] Chang CH, Qiu J, O'Sullivan D, Buck MD, Noguchi T, Curtis JD, et al. Metabolic Competition in the Tumor Microenvironment Is a Driver of Cancer Progression. *Cell* 2015;162(6):1229-41.

- [71] Zitvogel L, Galluzzi L, Smyth MJ, Kroemer G. Mechanism of action of conventional and targeted anticancer therapies: reinstating immunosurveillance. *Immunity* 2013;39(1):74-88.
- [72] Galsky MD, Hahn NM, Albany C, Fleming MT, Starodub A, Twardowski P, et al. Phase II trial of gemcitabine + cisplatin + ipilimumab in patients with metastatic urothelial cancer. *J Clin Oncol* 2016;34(2 suppl):abstr 357.
- [73] Galsky MD, Grande E, Davis I, De Santis M, Arranz J, Kikuchi E, et al. IMvig130: A randomized, phase III study evaluating first-line (1L) atezolizumab (atezo) as monotherapy and in combination with platinum-based chemotherapy (chemo) in patients (pts) with locally advanced or metastatic urothelial carcinoma (mUC). *J Clin Oncol* 2018;36(suppl 15)abstr TPS4589.
- [74] Sharma P, Callahan MK, Calvo A. Efficacy and safety of nivolumab plus ipilimumab in previously treated metastatic urothelial carcinoma: First results from the phase I/II CheckMate 032 study. Presented at: 2016 SITC Annual Meeting; November 9-13, 2016; National Harbor, MD.
- [75] Rosenberg J, Sharma P, De Braud F, Basso U, Calvo E, Bono P, et al. Nivolumab (N) alone or in combination with ipilimumab (I) in patients (pts) with platinum-pretreated metastatic urothelial carcinoma (mUC), including the nivolumab 1 mg/kg + ipilimumab 3 mg/kg expansion from CheckMate 032. *Ann Oncol* 2018;29(8 suppl):abstr LBA32.
- [76] Motz GT, Coukos G. The parallel lives of angiogenesis and immunosuppression: cancer and other tales. *Nat Rev Immunol* 2011;11(10):702-11.
- [77] Mazzola CR, Chin J. Targeting the VEGF pathway in metastatic bladder cancer. *Expert Opin Investig Drugs* 2015;24(7):913-27.
- [78] Choueiri TK, Ross RW, Jacobus S, Vaishampayan U, Yu EY, Quinn DI, et al. Double-blind, randomized trial of docetaxel plus vandetanib versus docetaxel plus placebo in platinum-pretreated metastatic urothelial cancer. *J Clin Oncol* 2012;30(5):507-12.
- [79] Twardowski P, Stadler WM, Frankel P, Lara PN, Ruel C, Chatta G, et al. Phase II study of Aflibercept (VEGF-Trap) in patients with recurrent or metastatic urothelial cancer, a California Cancer Consortium Trial. *Urology* 2010;76(4):923-6.
- [80] Balar AV, Apolo AB, Ostrovnaya I, Mironov S, Iasonos A, Trout A, et al. Phase II study of gemcitabine, carboplatin, and bevacizumab in patients with advanced unresectable or metastatic urothelial cancer. *J Clin Oncol* 2013;31(6):724-30.
- [81] Geldart T, Chester J, Casbard A, Crabb S, Elliott T, Protheroe A, et al. SUCCINCT: an open-label, single-arm, non-randomised, phase 2 trial of gemcitabine and cisplatin chemotherapy in combination with sunitinib as first-line treatment for patients with advanced urothelial carcinoma. *Eur Urol* 2015;67(4):599-602.
- [82] Krege S, Rexer H, vom Dorp F, de Geeter P, Klotz T, Retz M, et al. Prospective randomized double-blind multicentre phase II study comparing gemcitabine and cisplatin plus sorafenib chemotherapy with gemcitabine and cisplatin plus placebo in locally advanced and/or metastasized urothelial cancer: SUSE (AUO-AB 31/05). *BJU Int* 2014;113(3):429-36.
- [83] Dreicer R, Li H, Stein M, DiPaola R, Eleff M, Roth BJ, et al. Phase 2 trial of sorafenib in patients with advanced urothelial cancer: a trial of the Eastern Cooperative Oncology Group. *Cancer* 2009;115(18):4090-5.
- [84] Petrylak DP, de Wit R, Chi KN, Drakaki A, Sternberg CN, Nishiyama H, et al. Ramucirumab plus docetaxel versus placebo plus docetaxel in patients with locally advanced or metastatic urothelial carcinoma after platinum-based therapy (RANGE): a randomised, double-blind, phase 3 trial. *Lancet* 2017;390(10109):2266-77.

- [85] Hahn NM, Stadler WM, Zon RT, Waterhouse D, Picus J, Nattam S, et al. Phase II trial of cisplatin, gemcitabine, and bevacizumab as first-line therapy for metastatic urothelial carcinoma: Hoosier Oncology Group GU 04-75. *J Clin Oncol* 2011;29(12):1525-30.
- [86] Sridhar SS, Winquist E, Eisen A, Hotte SJ, McWhirter E, Tannock IF, et al. A phase II trial of sorafenib in first-line metastatic urothelial cancer: a study of the PMH Phase II Consortium. *Invest New Drugs* 2011;29(5):1045-9.
- [87] Bellmunt J, Gonzalez-Larriba JL, Prior C, Maroto P, Carles J, Castellano D, et al. Phase II study of sunitinib as first-line treatment of urothelial cancer patients ineligible to receive cisplatin-based chemotherapy: baseline interleukin-8 and tumor contrast enhancement as potential predictive factors of activity. *Ann Oncol* 2011;22(12):2646-53.
- [88] Gallagher DJ, Al-Ahmadie H, Ostrovnya I, Gerst SR, Regazzi A, Garcia-Grossman I, et al. Sunitinib in urothelial cancer: clinical, pharmacokinetic, and immunohistochemical study of predictors of response. *Eur Urol* 2011;60(2):344-9.
- [89] Necchi A, Mariani L, Zaffaroni N, Schwartz LH, Giannatempo P, Crippa F, et al. Pazopanib in advanced and platinum-resistant urothelial cancer: an open-label, single group, phase 2 trial. *Lancet Oncol* 2012;13(8):810-6.
- [90] Pili R, Qin R, Flynn PJ, Picus J, Millward M, Ho WM, et al. A phase II safety and efficacy study of the vascular endothelial growth factor receptor tyrosine kinase inhibitor pazopanib in patients with metastatic urothelial cancer. *Clin Genitourin Cancer* 2013;11(4):477-83.
- [91] Galsky MD, Hahn NM, Powles T, Hellerstedt BA, Lerner SP, Gardner TA, et al. Gemcitabine, Cisplatin, and sunitinib for metastatic urothelial carcinoma and as preoperative therapy for muscle-invasive bladder cancer. *Clin Genitourin Cancer* 2013;11(2):175-81.
- [92] Jones RJ, Hussain SA, Protheroe AS, Birtle A, Chakraborti P, Huddart RA, et al. Randomized Phase II Study Investigating Pazopanib Versus Weekly Paclitaxel in Relapsed or Progressive Urothelial Cancer. *J Clin Oncol* 2017;35(16):1770-7.
- [93] Apolo AB, Parnes H, Francis D, Cordes L, Berninger M, Lamping E, et al. A phase II study of cabozantinib in patients (pts) with relapsed or refractory metastatic urothelial carcinoma (mUC). *J Clin Oncol* 2016;34(15 suppl):abstr 4534.
- [94] Apolo AB, Mortazavi A, Stein M, Pal S, Davarpanah N, Parnes H, et al. A phase I study of cabozantinib plus nivolumab (CaboNivo) and ipilimumab (CaboNivoIpi) in patients (pts) with refractory metastatic urothelial carcinoma (mUC) and other genitourinary (GU) tumors. *J Clin Oncol* 2017;35(6 suppl):abstr 293.
- [95] Nadal R, Mortazavi A, Stein M, Pal S, Davarpanah N, Parnes H, et al. Final results of a phase I study of cabozantinib (cabo) plus nivolumab (nivo) and cabonivo plus ipilimumab (Ipi) in patients (pts) with metastatic urothelial carcinoma (mUC) and other genitourinary (GU) malignancies. *Ann Oncol* 2017;28(5 suppl):abstr 8460.
- [96] Nadal R, Mortazavi A, Stein M, Pal S, Lee D, Parnes H, et al. Clinical efficacy of cabozantinib plus nivolumab (CaboNivo) and CaboNivo plus ipilimumab (CaboNivoIpi) in patients (pts) with chemotherapy-refractory metastatic urothelial carcinoma (mUC) either naïve (n) or refractory (r) to checkpoint inhibitor (CPI). *J Clin Oncol* 2018;36(15 suppl):abstr 4528.
- [97] Petrylak DP, Tagawa ST, Kohli M, Eisen A, Canil C, Sridhar SS, et al. Docetaxel As Monotherapy or Combined With Ramucirumab or Icrucumab in Second-Line Treatment for Locally Advanced or Metastatic Urothelial Carcinoma: An Open-Label, Three-Arm, Randomized Controlled Phase II Trial. *J Clin Oncol* 2016;34(13):1500-9.

- [98] Narayanan S, Lam A, Vaishampayan U, Harshman L, Fan A, Pachynski R, et al. Phase II Study of Pazopanib and Paclitaxel in Patients With Refractory Urothelial Cancer. *Clin Genitourin Cancer* 2016;14(5):432-7.
- [99] Neal DE, Sharples L, Smith K, Fennelly J, Hall RR, Harris AL. The epidermal growth factor receptor and the prognosis of bladder cancer. *Cancer* 1990;65(7):1619-25.
- [100] Fleischmann A, Rotzer D, Seiler R, Studer UE, Thalmann GN. Her2 amplification is significantly more frequent in lymph node metastases from urothelial bladder cancer than in the primary tumours. *Eur Urol* 2011;60(2):350-7.
- [101] Iyer G, Al-Ahmadie H, Schultz N, Hanrahan AJ, Ostrovnaya I, Balar AV, et al. Prevalence and co-occurrence of actionable genomic alterations in high-grade bladder cancer. *J Clin Oncol* 2013;31(25):3133-40.
- [102] Petrylak DP, Tangen CM, Van Veldhuizen PJ, Jr., Goodwin JW, Twardowski PW, Atkins JN, et al. Results of the Southwest Oncology Group phase II evaluation (study S0031) of ZD1839 for advanced transitional cell carcinoma of the urothelium. *BJU Int* 2010;105(3):317-21.
- [103] Philips GK, Halabi S, Sanford BL, Bajorin D, Small EJ. A phase II trial of cisplatin (C), gemcitabine (G) and gefitinib for advanced urothelial tract carcinoma: results of Cancer and Leukemia Group B (CALGB) 90102. *Ann Oncol* 2009;20(6):1074-9.
- [104] Hussain M, Petrylak DP, Dunn R, Vaishampayan U, Lara PN, Chatta G, et al. Trastuzumab (T), paclitaxel (P), carboplatin (C), and gemcitabine (G) in advanced HER2-positive urothelial carcinoma: results of a multicenter phase II NCI trial. *J Clin Oncol* 2005;23(16 suppl):abstr 4507.
- [105] Hussain M, Daignault S, Agarwal N, Grivas PD, Siefker-Radtke AO, Puzanov I, et al. A randomized phase 2 trial of gemcitabine/cisplatin with or without cetuximab in patients with advanced urothelial carcinoma. *Cancer* 2014;120(17):2684-93.
- [106] Wulfing C, Machiels JP, Richel DJ, Grimm MO, Treiber U, De Groot MR, et al. A single-arm, multicenter, open-label phase 2 study of lapatinib as the second-line treatment of patients with locally advanced or metastatic transitional cell carcinoma. *Cancer* 2009;115(13):2881-90.
- [107] Choudhury NJ, Campanile A, Antic T, Yap KL, Fitzpatrick CA, Wade JL, 3rd, et al. Afatinib Activity in Platinum-Refractory Metastatic Urothelial Carcinoma in Patients With ERBB Alterations. *J Clin Oncol* 2016;34(18):2165-71.
- [108] Milowsky MI, Dittrich C, Duran I, Jagdev S, Millard FE, Sweeney CJ, et al. Phase 2 trial of dovitinib in patients with progressive FGFR3-mutated or FGFR3 wild-type advanced urothelial carcinoma. *Eur J Cancer* 2014;50(18):3145-52.
- [109] Nogova L, Sequist LV, Perez Garcia JM, Andre F, Delord JP, Hidalgo M, et al. Evaluation of BGJ398, a Fibroblast Growth Factor Receptor 1-3 Kinase Inhibitor, in Patients With Advanced Solid Tumors Harboring Genetic Alterations in Fibroblast Growth Factor Receptors: Results of a Global Phase I, Dose-Escalation and Dose-Expansion Study. *J Clin Oncol* 2017;35(2):157-65.
- [110] Pal SK, Rosenberg JE, Hoffman-Censits JH, Berger R, Quinn DI, Galsky MD, et al. Efficacy of BGJ398, a Fibroblast Growth Factor Receptor 1-3 Inhibitor, in Patients with Previously Treated Advanced Urothelial Carcinoma with FGFR3 Alterations. *Cancer Discov* 2018;8(7):812-21.
- [111] Kilgour E, Ferry D, Saggese M, Arkenau H, Rooney C, Smith N, et al. Exploratory biomarker analysis of a phase I study of AZD4547, an inhibitor of fibroblast growth factor

- receptor (FGFR), in patients with advanced solid tumors. *J Clin Oncol* 2014;32(15 suppl):abstr 11010.
- [112] Voss M, Hierro C, Heist R, Cleary J, Meric-Bernstam F, Gandhi L, et al. Debio 1347, an oral FGFR inhibitor: Results from a first-in-human, phase 1 dose-escalation study in patients with FGFR genomically activated advanced solid tumors. *J Clin Oncol* 2017;35(15 suppl):abstr 2500.
- [113] Joerger M, Soo R, Cho B, Mendivil A, Sayehli C, Richly H, et al. Phase I study of the pan-fibroblast growth factor receptor (FGFR) inhibitor BAY 1163877 with expansion cohorts for subjects based on tumor FGFR mRNA expression levels. *Ann Oncol* 2016;27(6):1-36.
- [114] Kuboki Y, Matsubara N, Bando H, Shitara K, Yoh K, Kojima T, et al. First-in-human study of TAS-120, a highly selective covalent oral fibroblast growth factor receptor (FGFR) inhibitor, in patients with advanced solid tumors. *Ann Oncol* 2017;28(5 suppl):abstr 372PD.
- [115] O'Donnell P, Goldman J, Gordon M, Shih K, Choi Y, Lu D, et al. A phase I dose-escalation study of MFGR1877S, a human monoclonal anti-fibroblast growth factor receptor 3 (FGFR3) antibody, in patients with advanced solid tumors. *Eur J Cancer* 2012;48(6 suppl):191-2.
- [116] Bellmunt J, Pal S, Picus J, Kohli M, Arriaga Y, Milowsky MI, et al. Safety and efficacy of docetaxel + B-701, a selective inhibitor of FGFR3, in subjects with advanced or metastatic urothelial carcinoma. *J Clin Oncol* 2017;35(15 suppl):abstr 4540.
- [117] Morrison K, Challita-Eid PM, Raitano A, An Z, Yang P, Abad JD, et al. Development of ASG-15ME, a Novel Antibody-Drug Conjugate Targeting SLITRK6, a New Urothelial Cancer Biomarker. *Mol Cancer Ther* 2016;15(6):1301-10.
- [118] Petrylak DP, Heath E, Sonpavde G, George S, Morgans A, Eigl BJ, et al. Interim analysis of a phase 1 dose escalation trial of the antibody drug conjugate (ADC) AGS15E (ASG-15ME) in patients (Pts) with metastatic urothelial cancer (mUC). *Ann Oncol* 2016;27(6 suppl):abstr 780PD.
- [119] Petrylak DP, Perez R, Zhang J, Smith D, Ruether J, Sridhar SS, et al. A phase I study of enfortumab vedotin (ASG-22CE; ASG-22ME): Updated analysis of patients with metastatic urothelial cancer. *J Clin Oncol* 2017;35(15 suppl):abstr 106.
- [120] Rosenberg J, Sridhar SS, Zhang J, Smith D, Ruether J, Flaig T, et al. Updated results from the enfortumab vedotin phase 1 (EV-101) study in patients with metastatic urothelial cancer (mUC). *J Clin Oncol* 2018;36(15 suppl):4504.



### Conflict of Interest Statement

Joaquim Bellmunt has been a consultant for Agensys, Amgen, Astra Zeneca, Bayer, Eisai, Genentech, Janssen, Merck, Novartis, Pfizer, Sanofi, and Seattle Genetics; has received financial support for research from Novartis and Sanofi, and royalties for his UpToDate contribution in urothelial tumours. Rosa Nadal declares no competing interests.

ACCEPTED MANUSCRIPT

Table 1. Systemic therapies approved or designated as a breakthrough therapy since 2016 for advanced/metastatic urothelial carcinoma

Agent	Mechanism	FDA-approved indication
<b>Immunotherapies</b>		
Atezolizumab	Anti-PD-L1 antibody	As monotherapy for: <ul style="list-style-type: none"> <li>- <b>Second-line:</b> Patients with advanced or metastatic UC after platinum containing regimen failure</li> <li>- <b>Frontline:</b> PD-L1 positive (PD-L1 expression on immune cells of &gt;5%) advanced or metastatic UC and not eligible for cisplatin-containing therapy or patients who are ineligible for any platinum-based agent</li> </ul>
Pembrolizumab	Anti-PD-1 antibody	As monotherapy for: <ul style="list-style-type: none"> <li>- <b>Second-line:</b> Patients with advanced or metastatic UC after platinum containing regimen failure</li> <li>- <b>Frontline:</b> Patients with PD-L1 positive (CPS ≥10 for PD-L1) advanced or metastatic UC and not eligible for cisplatin-containing therapy or patients who are ineligible for any platinum-based agent</li> </ul>
Nivolumab	Anti-PD-1 antibody	As monotherapy for patients with advanced or metastatic UC after platinum containing regimen failure
Durvalumab	Anti-PD-L1 antibody	As monotherapy for patients with advanced or metastatic UC after platinum containing regimen failure
Avelumab	Anti-PD-L1 antibody	As monotherapy for patients with advanced or metastatic UC after platinum containing regimen failure
<b>Targeted Therapy</b>		
Erdafitinib *	FGFR inhibitor	As monotherapy for patients with locally advanced or metastatic UC, whose tumors have certain <i>FGFR</i> genetic alterations

PD-L1, programmed death-ligand 1; UC, urothelial carcinoma; PD-1, Programmed cell death-1; CPS, combined positive scores; FGFR, fibroblast growth factor receptor

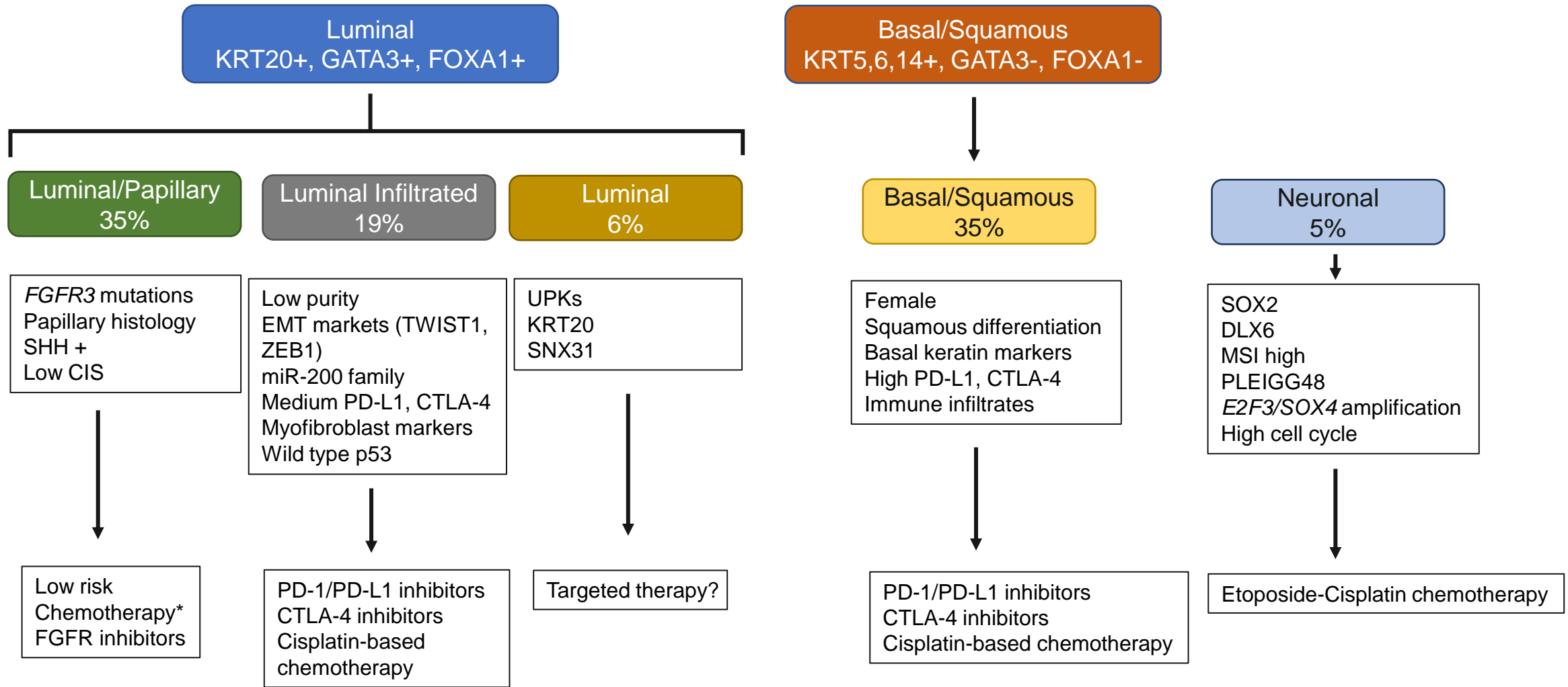
\* Designated as a breakthrough therapy

**Table 2. First-line immunotherapy trials**

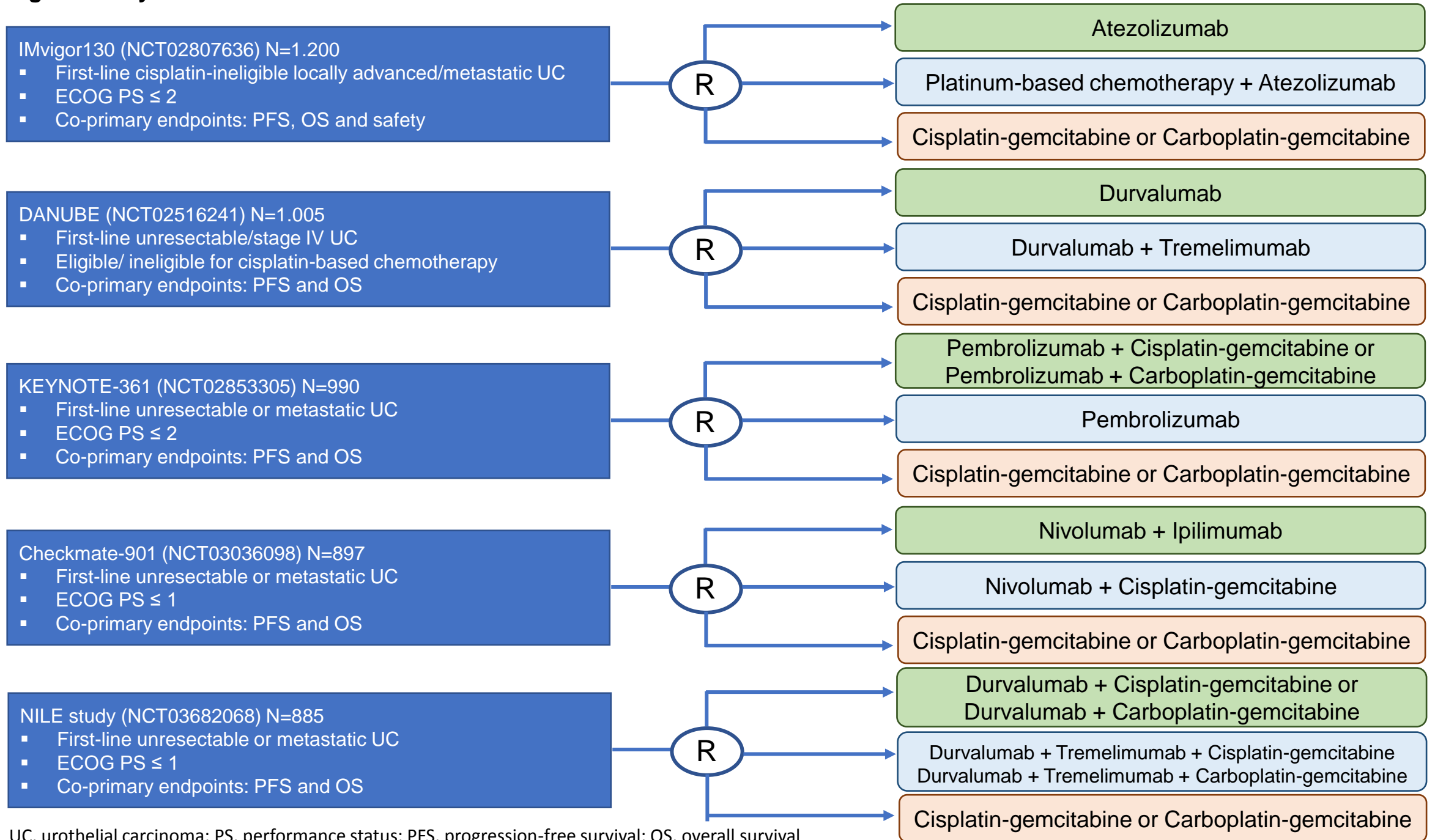
	<b>Atezolizumab</b>	<b>Pembrolizumab</b>
Sample Size	119	370
ECOG PS 2	20%	42%
Visceral Metastasis	65%	85%
Overall Response Rate	23% (28% in IC 2/3 patients)	24%; CR 6% (ORR 37% and CR 13%, respectively, in PD-L1-positive [CPS > 10%])
Median duration of response	Not reached at 17.2 months of median follow-up	Not reached at 8 months of median follow-up
Median Progression-free survival	2.1 months	2.3 months
Overall Survival; median, confidence interval	15.9 months (10.4-NE)	11.5 months (10.0-13.3)
Grade 3 and/or 4 TRAEs	5%	16%

PS, performance status; IC, immunohistochemistry; CR: complete response; ORR, overall response rate; PD-L1, programmed cell death ligand-1; CPS, combined positive score NE, non-evaluable; TRAEs, treatment-related adverse events.

**Figure 1. Classification of urothelial carcinomas by molecular markers and proposed treatment**

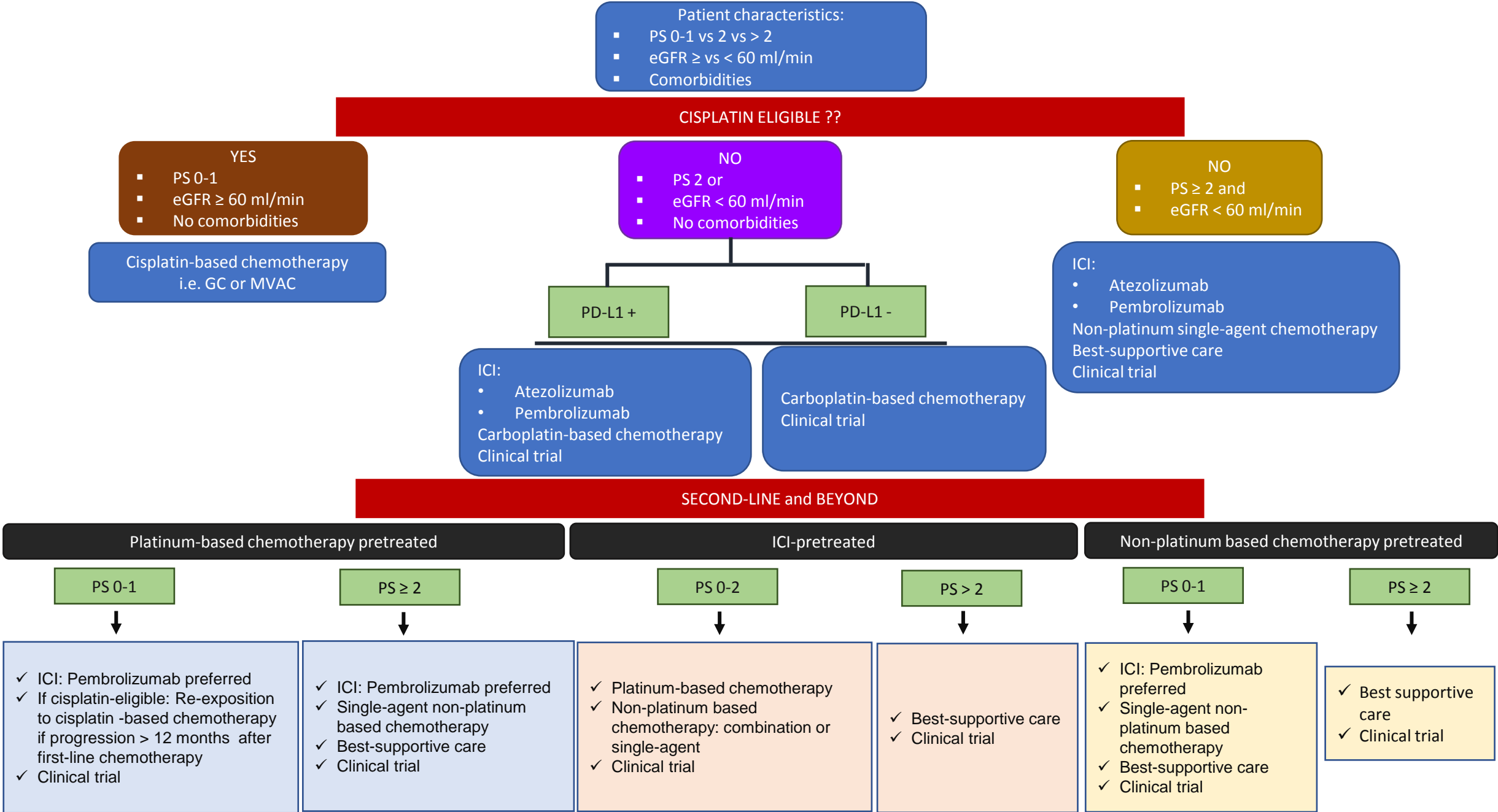


**Figure 2. Key first-line Phase III trials of anti-PD1/PD-L1 antibodies in urothelial carcinoma**



UC, urothelial carcinoma; PS, performance status; PFS, progression-free survival; OS, overall survival

**Figure 3. Metastatic Bladder Cancer Management Algorithm**



## Highlights

- Cisplatin-based chemotherapy has been the mainstay of treatment for metastatic urothelial carcinoma for more than three decades
- Since 2016, five immune checkpoint inhibitors have been approved for the treatment of metastatic bladder cancer in the second-line setting
- The role of frontline immune checkpoint inhibitors is restricted to metastatic bladder cancer patients with PD-L1 positivity and who are platinum-ineligible
- The TCGA and other research groups have used genomics to classify bladder cancer tumors into molecular subtypes which can predict response to particular types of treatment
- Erdafitinib has been granted breakthrough designation by the FDA for the treatment of *FGFR alteration*-positive advanced bladder cancer and enfortumab vedotin for patients with advanced urothelial cancer who previously received immune checkpoint therapy,

ACCEPTED MANUSCRIPT