




ORIGINAL RESEARCH

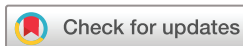Influence of the EULAR recommendations for the use of imaging in large vessel vasculitis in the diagnosis of giant cell arteritis: results of the ARTESER register

Eugenio De Miguel ¹, Jesús T Sanchez-Costa,² Paula Estrada,³ Alejandro Muñoz,⁴ Cristina Valero Martínez,⁵ Patricia Moya Alvarado,⁶ María Jesús García-Villanueva,⁷ Vanessa A Navarro Angeles,³ Carlos Galisteo Lencastre Da Veiga,⁸ Anne Riveros Frutos,⁹ Jose A Román Ivorra,¹⁰ Selena Labrada Arrabal,¹¹ Margarida Vasques Rocha,¹² Carlota L Iñiguez,¹³ María García-Gonzalez,¹⁴ Clara Molina-Almeda,¹⁵ María Alcalde Villar,¹⁶ Antonio Juan Mas,¹⁷ Miguel A Gonzalez-Gay ¹⁸, Ricardo Blanco ¹⁸

To cite: De Miguel E, Sanchez-Costa JT, Estrada P, *et al.* Influence of the EULAR recommendations for the use of imaging in large vessel vasculitis in the diagnosis of giant cell arteritis: results of the ARTESER register. *RMD Open* 2022;**8**:e002507. doi:10.1136/rmdopen-2022-002507

► Additional supplemental material is published online only. To view, please visit the journal online (<http://dx.doi.org/10.1136/rmdopen-2022-002507>).

Received 19 July 2022
Accepted 19 October 2022



© Author(s) (or their employer(s)) 2022. Re-use permitted under CC BY-NC. No commercial re-use. See rights and permissions. Published by BMJ.

For numbered affiliations see end of article.

Correspondence to
Dr Eugenio De Miguel;
eugenio.demiguel@gmail.com

ABSTRACT

Objective The main study objective was to determine how giant cell arteritis (GCA) is diagnosed in our clinical practice and whether the EULAR recommendations have influenced the diagnostic procedures used.

Methods ARTERitis of the Rheumatology Spanish Society -Sociedad Española de Reumatología (ARTESER) is a multicentre observational retrospective study conducted in 26 hospitals with support from the Spanish Society of Rheumatology. All patients diagnosed with GCA between 1 June 2013 and 29 March 2019 were included. The gold standard for the diagnosis of GCA was the judgement of the physician in charge, according to clinical criteria, supported by data available from laboratory tests, imaging studies (ultrasound, positron emission tomography (PET) and MRI/CT angiography) and temporal artery biopsy (TAB) when available.

Results We included 1675 patients with GCA (mean age±SD (76.9±8.1) years, 1178 women (70.3%)). Of these, 776 patients had a positive TAB (46.3%), 503 (30.0%) positive ultrasound, 245 positive PET (14.6%) and 64 positive MRI/CT angiography (3.8%). These percentages changed substantially over the study. From 2013 to 2019, the use of ultrasound in diagnosis grew from 25.8% to 52.9% and PET from 12.3% to 19.6%, while use of TAB decreased from 50.3% to 33.3%.

Conclusions Biopsy was the most widely used diagnostic test for confirming GCA, but use of imaging as a diagnostic tool has grown in recent years. Following publication of the 2018 EULAR recommendations, ultrasound has displaced biopsy as the first-line diagnostic test; TAB was performed in a third and PET in a fifth of cases.

INTRODUCTION

Giant cell arteritis (GCA) is the most common form of systemic vasculitis in adults.^{1 2} It is associated with considerable morbidity; vision

WHAT IS ALREADY KNOWN ON THIS TOPIC

- ⇒ Temporal artery biopsy has been the gold standard for confirming the diagnosis of giant cell arteritis (GCA), but its sensitivity is moderate. In recent years, various imaging modalities, including vascular ultrasound, have shown to have high sensitivity and specificity for GCA diagnosis.
- ⇒ Ultrasound is now recommended as a first-line diagnostic tool in current 2018 EULAR recommendations on the use of imaging in GCA and biopsy or additional imaging tests are considered redundant, in patients with positive imaging and a high clinical probability of GCA or unnecessary when ultrasound is negative and the clinical pretest probability is low.

WHAT THIS STUDY ADDS

- ⇒ The results show, as the diagnosis methods of GCA are changing in the last years and how after the publication of the 2018 EULAR recommendations on the use of imaging in large vessel vasculitis, ultrasound has displaced the biopsy as main support in the diagnosis of GCA and other image techniques are also increasing their use.

HOW THIS STUDY MIGHT AFFECT RESEARCH, PRACTICE OR POLICY

- ⇒ The use of ultrasound and other imaging techniques will expand the spectrum of GCA covering not only cranial involvement but also the large extracranial vessels.
- ⇒ The use of ultrasound will improve accuracy and early diagnosis of GCA. Image training should be enhanced in the coming years.

loss is common if initiation of treatment is delayed and stroke and constitutional symptoms may occur. For decades, temporal artery biopsy (TAB) has been the gold standard

for confirming the diagnosis of GCA, but it has only a moderate sensitivity (of 40–60%), with false-negative results due to skip lesions and difficulties detecting involvement of extracranial arteries.³

In recent years, several studies have found various imaging modalities, including vascular ultrasound, MRI, CT and positron emission tomography (PET) to have high sensitivity and specificity for GCA.⁴ Evidence from imaging in the diagnosis of the disease has allowed widening of the concept from cranial disease diagnosed by TAB to isolated or associated involvement of large extracranial vessels.^{5,6} Ultrasound is now recommended as a first-line diagnostic tool in GCA in current European guidelines, and TAB or additional imaging tests are considered redundant in patients with positive imaging and a high clinical probability of GCA. In patients with a low clinical probability and a negative imaging result, the diagnosis of GCA can be considered unlikely. In all other situations, additional efforts towards a diagnosis are necessary.⁷

To standardise research studies, various classification systems have been used. Currently, the 1990 American College of Rheumatology (ACR) criteria for the classification of GCA⁸ are probably the most widely used, but the positive predictive value of these criteria is based on the high specificity of TAB, though it has been reported to have insufficient sensitivity. Therefore, in the latest EULAR recommendations on the use of imaging in GCA,^{7,9} imaging techniques were accepted as new useful tools in GCA with high sensitivity and specificity in the diagnosis and assessment of large vessel vasculitis. This means that the GCA classification criteria are currently under discussion and evolution. Meanwhile, the diagnosis is based on the experience and judgement of the clinician. Our main objective was to determine how TAB and the new imaging techniques are being used in the diagnosis of GCA in recent years and whether the publication of the EULAR recommendations has changed diagnostic practice in our hospitals.

METHODS

Study Design

ARTESER is a multicentre observational retrospective longitudinal study conducted in 26 hospitals with the support of the Spanish Society of Rheumatology. All patients diagnosed with GCA between 1 June 2013 and 29 March 2019 (date of approval by first ethics review board) were included. The data were obtained by review of medical records.

Study population

All consecutive patients were included if they were aged 50 years or older and had a confirmed diagnosis of GCA, that is, they met at least one of the following criteria: positive result in an objective diagnostic test, at least three 1990 ACR criteria for GCA satisfied, and/or a diagnosis made based on the clinical judgement of the investigator.

A list of patients with a diagnosis of GCA was obtained during the recruitment period, by consulting the appropriate databases according to the characteristics of each hospital, namely, those of the departments of pathology, internal medicine, neurology or rheumatology, and each patient's full clinical record was obtained to allow the collection of data required to meet the objectives of the study. These data were gathered over a period of 17 months.

Variables

The types of data collected in this substudy were: (1) social and demographic characteristics: age at inclusion, sex and race (Caucasian, Hispanic, African, Latin American, Others); (2) clinical characteristics at diagnosis: initial symptoms of GCA, date of diagnosis of GCA, clinical manifestations (headache, scalp hypersensitivity, facial pain, dysphagia, jaw claudication, amaurosis fugax, permanent blindness, diplopia, confirmed optic neuritis, vertigo, hearing loss, transient ischaemic attack, stroke, upper and/or lower limb claudication, polymyalgia rheumatica, peripheral synovitis, asthenia, anorexia, weight loss, fever); (3) comorbidities at diagnosis; (4) laboratory test results: erythrocyte sedimentation rate and standard C reactive protein level; (5) date and result of the TAB and/or other imaging techniques (ultrasound, PET, MRI, CT) and (6) use of glucocorticoids and immunosuppressants (methotrexate, leflunomide, azathioprine and biological therapy such as anti-interleukin 6) at baseline and during the follow-up of the patients.

Statistical analysis

Continuous data were described as mean and SD (mean±SD) and categorical variables such as diagnostic test results as numbers and percentages. All analyses were performed using IBM SPSS V.28.0 software.

RESULTS

During the study period, we included 1675 patients with GCA (mean age±SD of 76.9±8.1 years, 1178 women (70.3%)) from 26 hospitals. Analysing data related to the main objective of the study, 776 patients were found to have a positive TAB (46.3%), 503 (30.0%) a positive ultrasound, 245 a positive PET (14.6%) and 64 a positive MRI/CT angiography (3.8%). These percentages changed substantially over the study observation time, with the use of TAB decreasing and that of imaging techniques, especially ultrasound, increasing (figure 1).

Many patients underwent several complementary diagnostic procedures. Analysing patients with positive results in several objective diagnostic tests confirming their GCA diagnosis, it was found that TAB was the only specific test performed in 531 patients (31.7%), ultrasound in 257 (15.3%), PET in 135 patients (8.1%) and MRI/CT angiography in 14 patients (0.8%). Furthermore, the data showed that the diagnosis had been made based on clinical criteria or physician's judgement without TAB

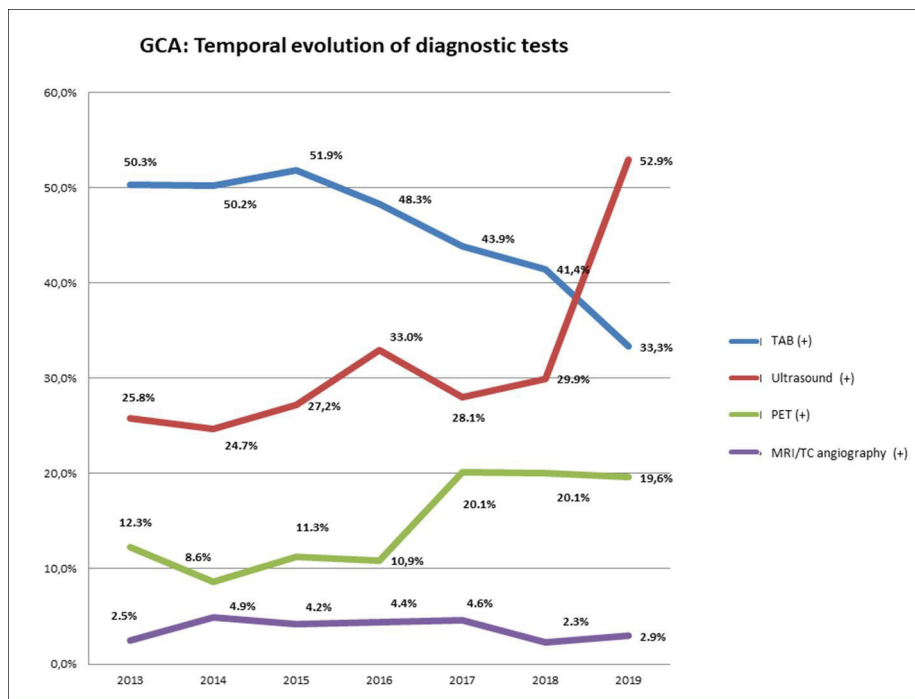


Figure 1 Rates of use of diagnostic tests for GCA over the study period. GCA, giant cell arteritis; PET, positron emission tomography; TAB, temporal artery biopsy.

or imaging tests in 417 patients (24.9%). Between 2013 and 2019, the percentage of patients in which ultrasound was used for diagnosis increased from 25.8% to 52.9%, and PET use grew from 12.3% to 19.6%, while TAB use decreased from 50.3% to 33.3%.

Analysing the subtypes of GCA by vessel size, the results showed 1091 patients had cranial involvement, 331 extracranial involvement and 170 patients had mixed patterns (cranial and extracranial), while in 253 patients, the subtype of vascular compromise was not recorded. The rate of extracranial involvement has increased in recent years coinciding with the growth in the use of imaging in the diagnosis, as is seen by comparing figures 1 and 2. The use of image or biopsy did not show significant

differences between patients with or without cranial symptoms. In the analysis of the results, the use of biopsy or image was clearly related with the hospital preferences or availability in every centre (online supplemental table S1).

DISCUSSION

The procedures to confirm the diagnosis of GCA have changed over the last decade. In a recent study based on data from a Danish register for 1 January 1996 to 31 December 2018, Therkildsen *et al* reported that the percentage of GCA patients diagnosed by TAB remained constant until 2016, after which it sharply declined from 70%–80% to 29%–39%; in contrast, the percentage of patients undergoing diagnostic imaging increased from 2% to 66% between 2000 and 2018.¹⁰ Similar patterns are observed in our nationwide register (ARTESER), TAB being the leading test for diagnosis in 2013, but its popularity declining such that, by 2019, it was only used in a third of cases. Diagnostic imaging, on the other hand, has become more popular, with ultrasound at the top of the list, it is used in 53% of patients in 2019, followed by PET-TC used in 20%. The diagnostic approach has changed progressively over time, probably associated with stronger evidence emerging and an increasing interest in extracranial vessel disease. After the emergence of the EULAR recommendations for the use of imaging in large vessel vasculitis in clinical practice⁷ and the publication of the definitions and reliability of elementary ultrasound lesions in GCA,¹¹ the use of ultrasound rose sharply, by as much as 20.3% in a year.

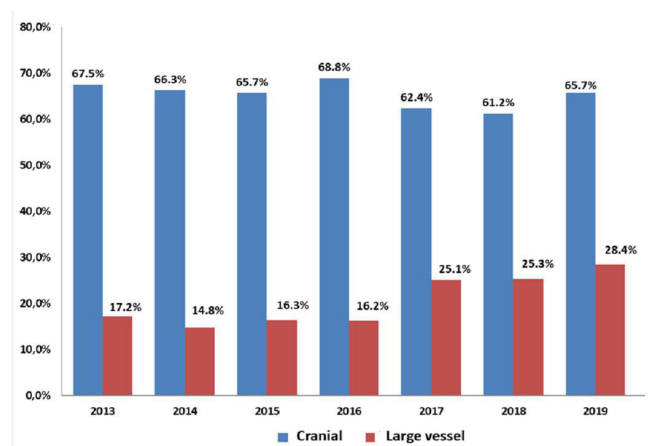


Figure 2 Rates of cranial and extracranial (large vessel) involvement in giant cell arteritis detected over the study period.

Another important finding associated with the introduction of imaging techniques for the assessment in GCA is the increase in the diagnosis of the large vessel vasculitis subtype, this increasing by 65%, with no decrease in the rate of diagnosis of cranial forms, which suggests that the inclusion of imaging leads to an expansion in the diagnosis of all GCA subtypes. This higher rate of diagnosis of large vessel involvement is consistent with recent publications that show a higher frequency of the large vessel subtype in this disease, and the value of imaging for improving the accuracy of GCA diagnosis.^{12 13}

Limitations of the study include its retrospective nature, which implies a risk of information bias caused by inaccurate recording of the data. To address this, all researchers had a previous meeting with the principal investigator to clarify the procedure for accurate retrieval of the data of interest. Another limitation of the study was the potential variability in the use of imaging tests and biopsies between the hospitals. The different hospitals have used the best standard methods and evidence in the use of PET, but the cited standards were changed along the time, PET studies. The US machine/probes and expertise of the ultrasonographers differ in the different hospitals. Nonetheless, with the participation of 26 hospitals across different regions and data collected on 1675 cases, we believe that the results are a good reflection of real clinical practice in Spain. An additional limitation is that we did not exclusively use the ACR classification criteria, since imaging tests are not yet included in these criteria. Our gold standard for diagnosis was the clinical judgement of the physician, and the results show that the adoption of image techniques in daily clinical practice could account for updating criteria for classifying the disease.

In summary, TAB was the most widely used diagnostic method for confirming GCA, but today, following the publication of the EULAR recommendations in 2018, ultrasound has displaced biopsy as the leading diagnostic test. The use of PET-TC for diagnosis is also growing, this type of imaging having been performed in around 20% of patients in the last 3 years of the study. There is a wide margin for improvement in the diagnosis of GCA; however, a quarter of diagnoses still being made clinically, without TAB or additional imaging tests. Concerning the subtypes of GCA, cranial involvement is the most common, but the diagnosis of the extracranial large vessel subtype has increased in recent years in line with the use of imaging, and the rate of this subtype detected is likely to increase further in the coming years.

Author affiliations

¹Hospital Universitario La Paz, Madrid, Madrid, Spain

²Rheumatology, Research Unit, Madrid, Madrid, SPAIN, Spain

³Rheumatology Department, Hospital de Sant Joan Despi Moisès Broggi, Sant Joan Despi, Spain

⁴Rheumatology Department, Hospital Universitario Virgen del Rocío Sevilla, Sevilla, Spain

⁵Rheumatology Department, Hospital Universitario de la Princesa, Madrid, Spain

⁶Rheumatology Department, Hospital de la Santa Creu i Sant Pau Barcelona, Barcelona, Spain

⁷Hospital Universitario Ramon y Cajal, Madrid, Madrid, Spain

⁸Rheumatology Department, Hospital Universitari Parc Tauli Sabadell, Sabadell, Spain

⁹Rheumatology Department, Hospital Germans Trias i Pujol, Badalona, Spain

¹⁰Rheumatology Department, Hospital Universitari i Politècnic La Fe, Valencia, Spain

¹¹Rheumatology Department, Hospital del Mar, Barcelona, Spain

¹²Rheumatology Department, Hospital Universitario Araba, Vitoria-Gasteiz, Spain

¹³Rheumatology, Hospital Universitario Lucus Augusti, Lugo, Galicia, Spain

¹⁴Hospital Universitario de Canarias, La Laguna, Canarias, Spain

¹⁵Rheumatology, Consorci Hospital General Universitari de València, Valencia, Comunitat Valenciana, Spain

¹⁶Rheumatology Department, Hospital Universitario Severo Ochoa Leganes, Leganes, Madrid, Spain

¹⁷Rheumatology Department, Hospital Universitari Son Llàtzer, Palma de Mallorca, Spain

¹⁸Rheumatology, Hospital Universitario Marqués de Valdecilla, IDIVAL, Santander, Cantabria, Spain

Acknowledgements To the Spanish Society of Rheumatology that has promoted and provided coverage for this study. To Roche for its financial contribution that made this epidemiological study possible.

Contributors DM and RB-A participated in the design of the work, the acquisition and interpretation of data, and were major contributors in writing the manuscript. J.T.S-C participated in the design of the work, the analysis and interpretation of data, and was a major contributor in writing the manuscript. PE, AM, CVM, PMA, M.J.G-V, V.A.NA, C.G.LDV, ARF, J.A.RI, SLA, MVR, C.L.I-U, MG-G, CM-A, MAV and AJM made substantial contributions to the acquisition of data. M.A.G-G participated in the design of the work. All authors revised the manuscript critically, and read and approved the final version.

Funding Roche contributes to the financial support of this study.

Competing interests EDM: Speakers bureau: Abbvie, Novartis, Pfizer, MSD, BMS, UCB, Roche, Grunental, Janssen, Sanofi; Paid instructor for: Janssen, Novartis, Roche; Consultant of: Abbvie, Novartis, Pfizer, Galapagos; Grant/research support from: Abbvie, Novartis, Pfizer. MAG-G: received grants/research supports from Abbvie, Jansen and Roche, and had consultation fees/participation in company sponsored speaker's bureau from Abbvie, Roche, Sanofi, Lilly, Novartis, GSK and Celgene. RB-A: received grants/research supports from Abbvie, MSD, and Roche, and had consultation fees/participation in company sponsored speaker's bureau from Abbvie, Pfizer, Roche, Bristol-Myers, Janssen, Lilly and MSD. CLI-U: received supports and speaker's fees from Pfizer, AbbVie, Fresenius - Kiabi, Novartis, GSK, Sanofi y Janssen por asistencia cursos y congresos. Other authors: None declared.

Patient consent for publication Not applicable.

Ethics approval This study involves human participants and was approved by 05/2019 Ethics Committee for Research with Medicines of Cantabria, Santander, Spain. The study was conducted following the principles outlined in the Declaration of Helsinki. Retrospective study in clinical records. It would not be possible to contact patients in most cases and was approved by the ethical board.

Provenance and peer review Not commissioned; externally peer reviewed.

Data availability statement Data are available upon reasonable request to the Spanish Society of Rheumatology.

Supplemental material This content has been supplied by the author(s). It has not been vetted by BMJ Publishing Group Limited (BMJ) and may not have been peer-reviewed. Any opinions or recommendations discussed are solely those of the author(s) and are not endorsed by BMJ. BMJ disclaims all liability and responsibility arising from any reliance placed on the content. Where the content includes any translated material, BMJ does not warrant the accuracy and reliability of the translations (including but not limited to local regulations, clinical guidelines, terminology, drug names and drug dosages), and is not responsible for any error and/or omissions arising from translation and adaptation or otherwise.

Open access This is an open access article distributed in accordance with the Creative Commons Attribution Non Commercial (CC BY-NC 4.0) license, which permits others to distribute, remix, adapt, build upon this work non-commercially, and license their derivative works on different terms, provided the original work is properly cited, appropriate credit is given, any changes made indicated, and the use is non-commercial. See: <http://creativecommons.org/licenses/by-nc/4.0/>.

ORCID iDs

Eugenio De Miguel <http://orcid.org/0000-0001-5146-1964>

Miguel A Gonzalez-Gay <http://orcid.org/0000-0002-7924-7406>

Ricardo Blanco <http://orcid.org/0000-0003-2344-2285>

REFERENCES

- 1 Gonzalez-Gay MA, Vazquez-Rodriguez TR, Lopez-Diaz MJ, *et al.* Epidemiology of giant cell arteritis and polymyalgia rheumatica. *Arthritis Rheum* 2009;61:1454–61.
- 2 Lawrence RC, Felson DT, Helmick CG, *et al.* Estimates of the prevalence of arthritis and other rheumatic conditions in the United States. Part II. *Arthritis Rheum* 2008;58:26–35.
- 3 Luqmani R, Lee E, Singh S, *et al.* The role of ultrasound compared to biopsy of temporal arteries in the diagnosis and treatment of giant cell arteritis (TABUL): a diagnostic accuracy and cost-effectiveness study. *Health Technol Assess* 2016;20:1–238.
- 4 Duftner C, Dejaco C, Sepriano A, *et al.* Imaging in diagnosis, outcome prediction and monitoring of large vessel vasculitis: a systematic literature review and meta-analysis Informing the EULAR recommendations. *RMD Open* 2018;4:e000612.
- 5 van der Geest KSM, Sandovici M, van Sleen Y, *et al.* Review: what is the current evidence for disease subsets in giant cell arteritis? *Arthritis Rheumatol* 2018;70:1366–76.
- 6 Tomelleri A, van der Geest KSM, Sebastian A. Disease stratification in giant cell arteritis to reduce relapses and prevent long-term vascular damage. *Lancet Rheumatol* 2021;60:4361–6.
- 7 Dejaco C, Ramiro S, Duftner C, *et al.* EULAR recommendations for the use of imaging in large vessel vasculitis in clinical practice. *Ann Rheum Dis* 2018;77:636–43.
- 8 Hunder GG, Bloch DA, Michel BA, *et al.* The American College of rheumatology 1990 criteria for the classification of giant cell arteritis. *Arthritis Rheum* 1990;33:1122–8.
- 9 Hellmich B, Agueda A, Monti S, *et al.* 2018 update of the EULAR recommendations for the management of large vessel vasculitis. *Ann Rheum Dis* 2020;79:19–30.
- 10 Therkildsen P, de Thurah A, Hansen IT, *et al.* Giant cell arteritis: a nationwide, population-based cohort study on incidence, diagnostic imaging, and glucocorticoid treatment. *Semin Arthritis Rheum* 2021;51:360–6.
- 11 Chrysidis S, Duftner C, Dejaco C, *et al.* Definitions and reliability assessment of elementary ultrasound lesions in giant cell arteritis: a study from the OMERACT large vessel vasculitis ultrasound Working group. *RMD Open* 2018;4:e000598.
- 12 Löffler C, Hoffend J, Benck U, *et al.* The value of ultrasound in diagnosing extracranial large-vessel vasculitis compared to FDG-PET/CT: a retrospective study. *Clin Rheumatol* 2017;36:2079–86.
- 13 Hop H, Mulder DJ, Sandovici M, *et al.* Diagnostic value of axillary artery ultrasound in patients with suspected giant cell arteritis. *Rheumatology* 2020;59:3676–84.